Block 03

Special figures

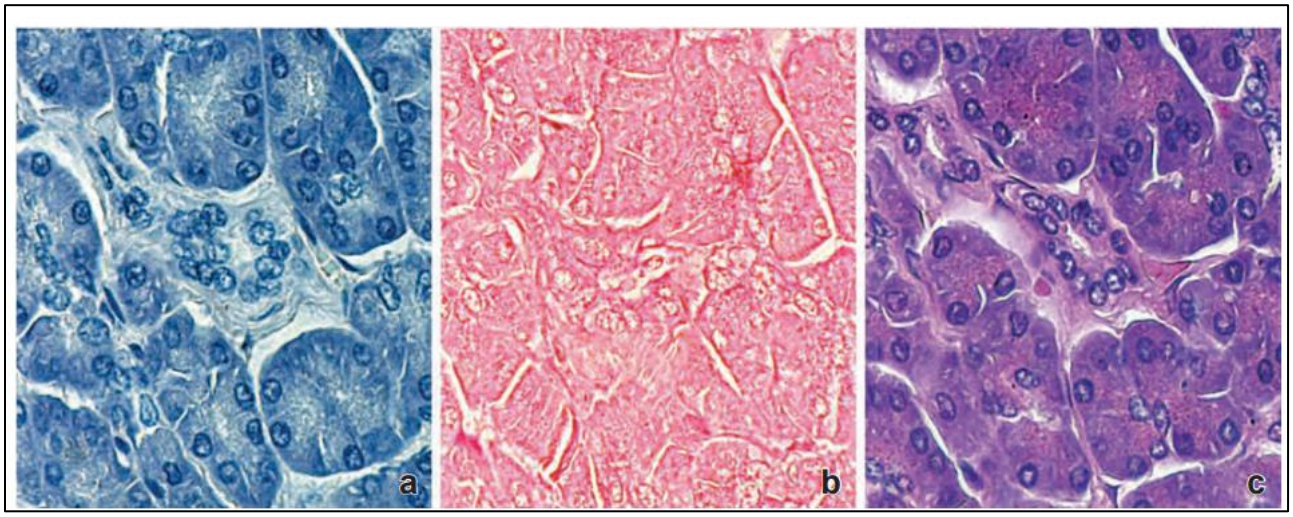

A series of tissue stained with Hematoxylin and eosin (H&E) staining respectively.

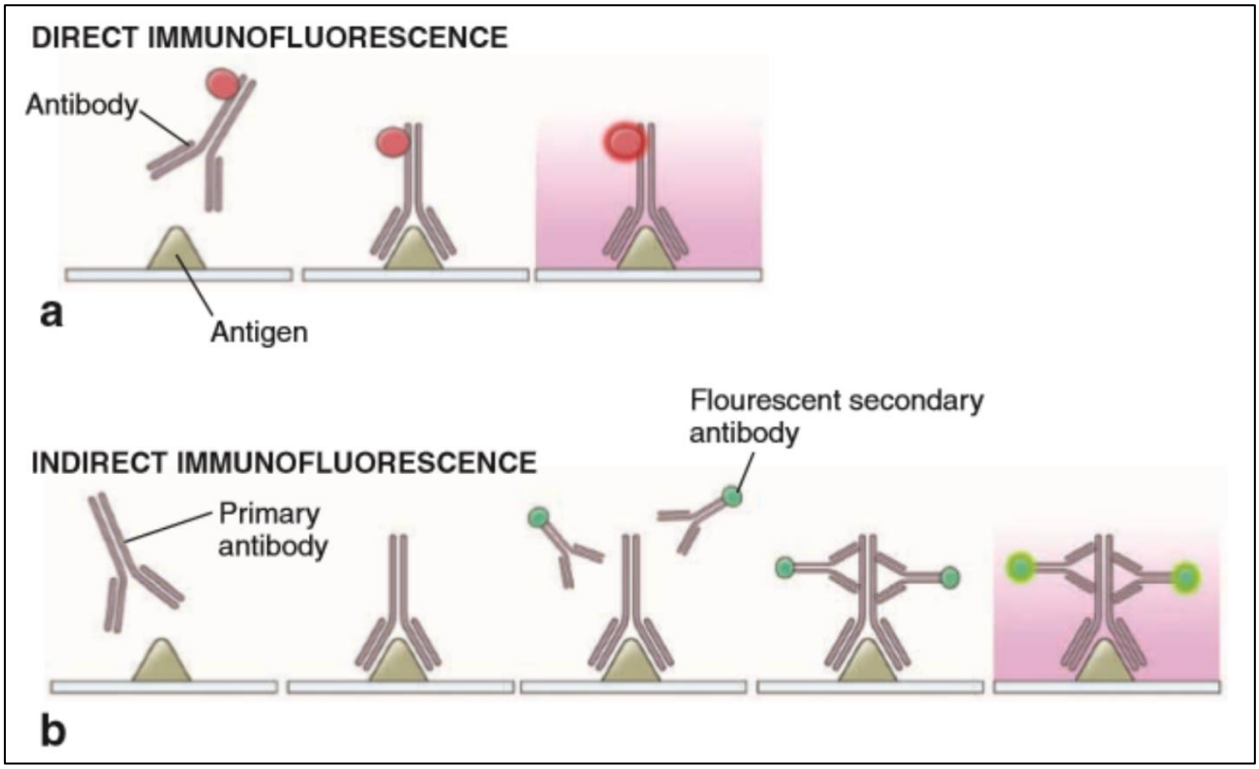

Mechanism of Direct and indirect immunofluorescence.

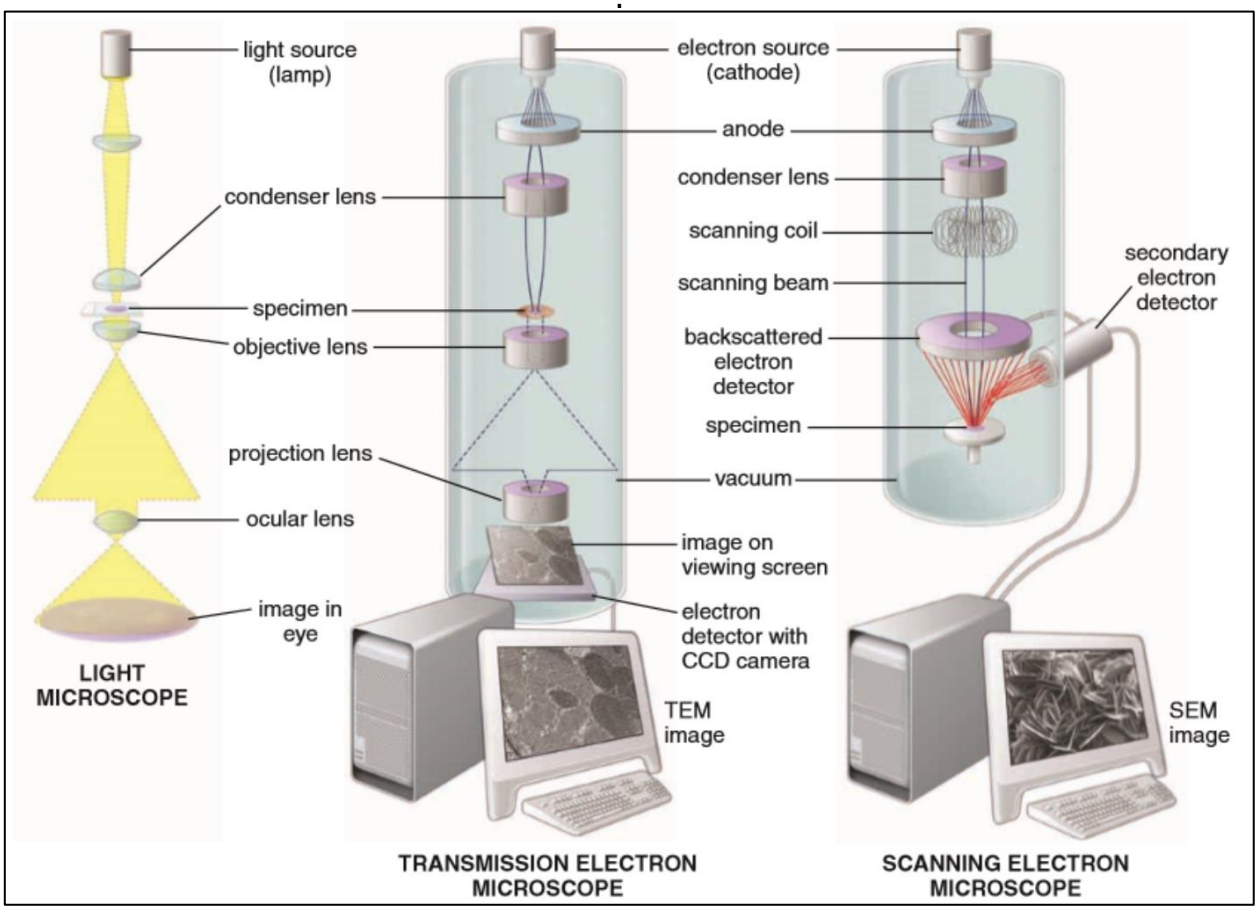

Diagram comparing the optical paths in different types of microscopes.

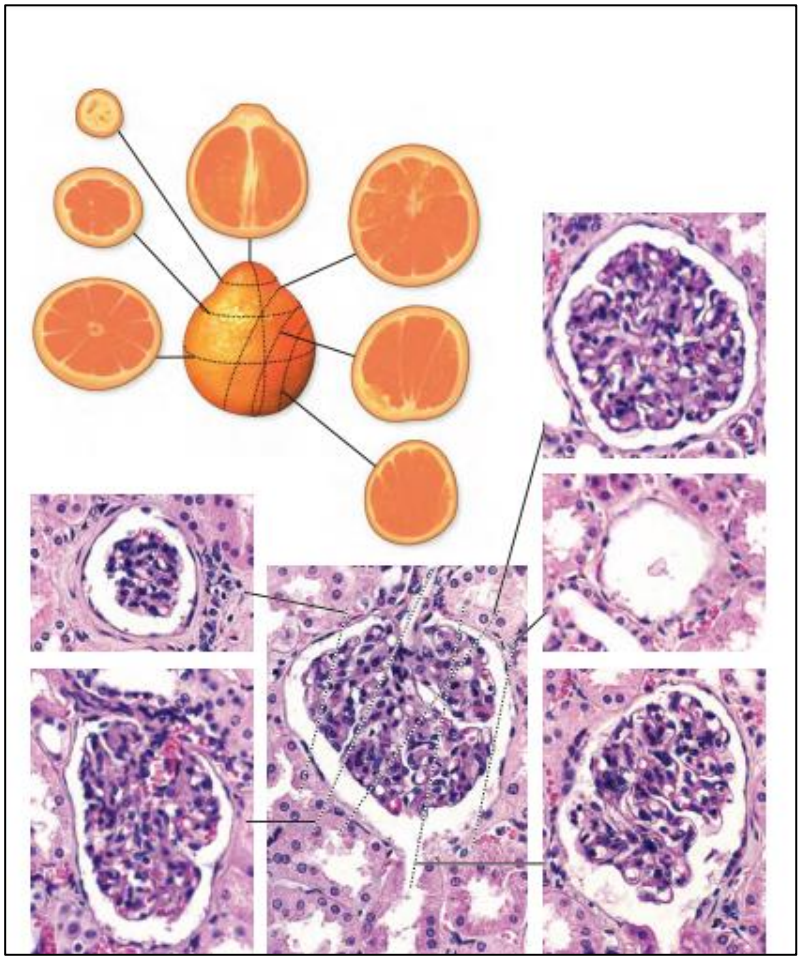

Example of sections from an orange and a kidney renal corpuscle.

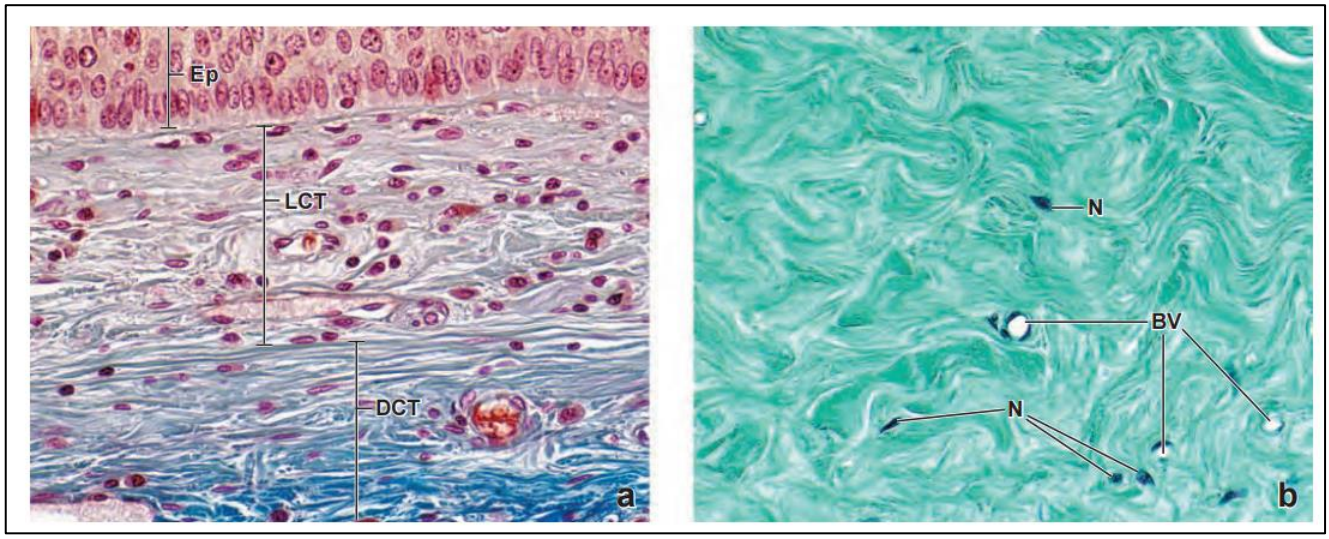

Loose and dense connective tissue satained with Mallory-Azan.

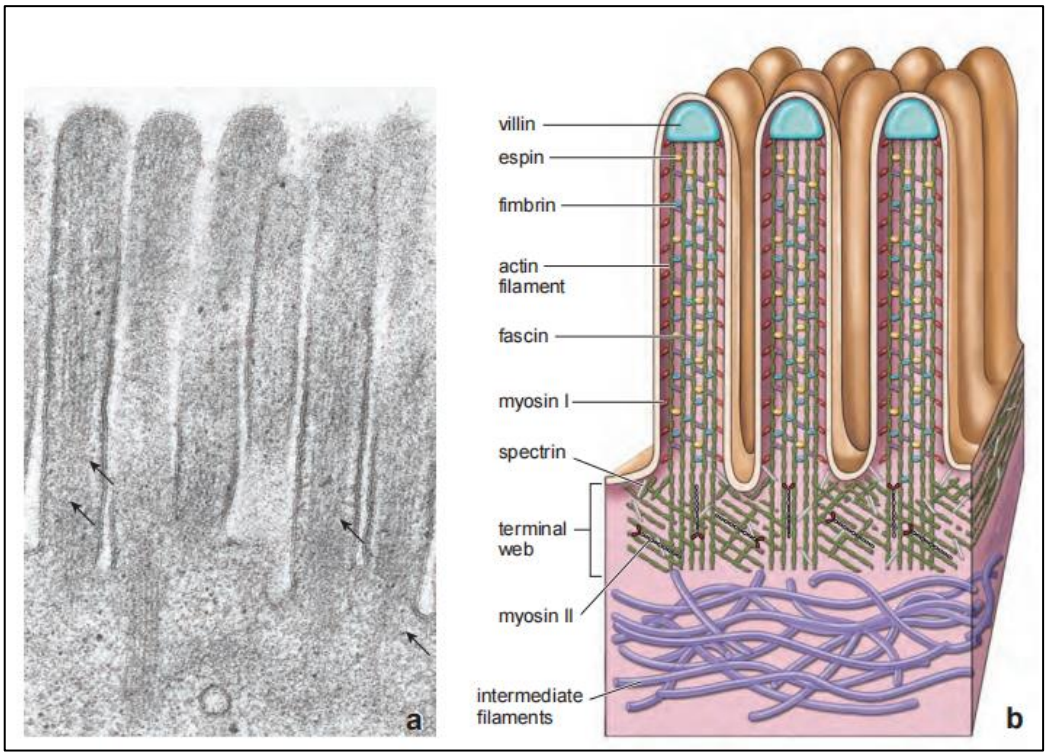

Molecular structure of microvilli.

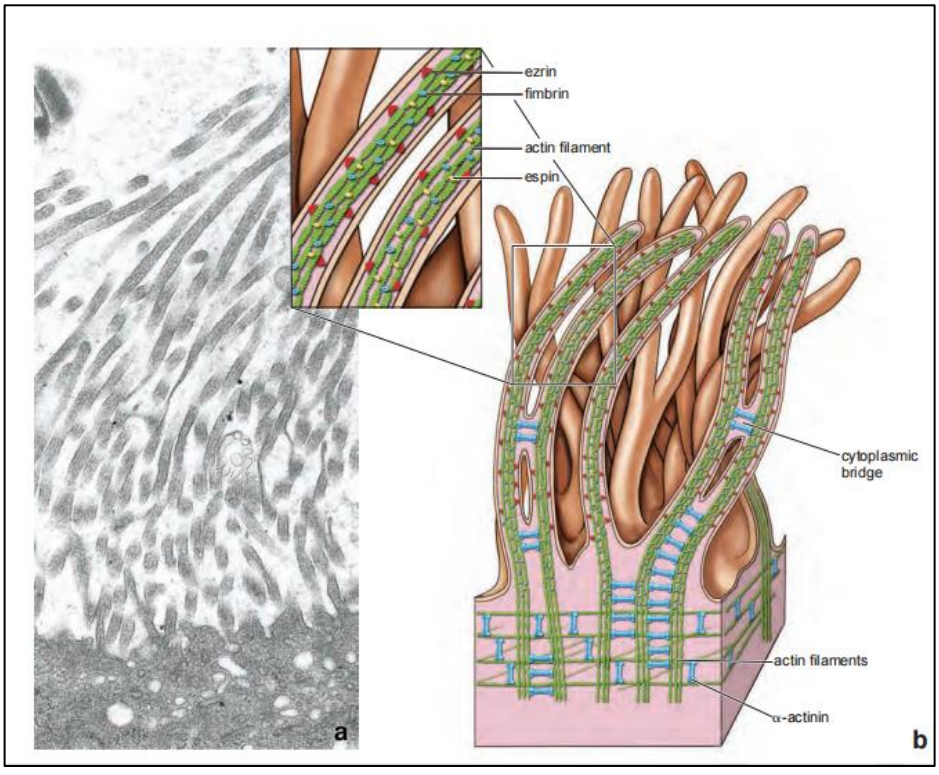

Molecular structure of stereocilia.

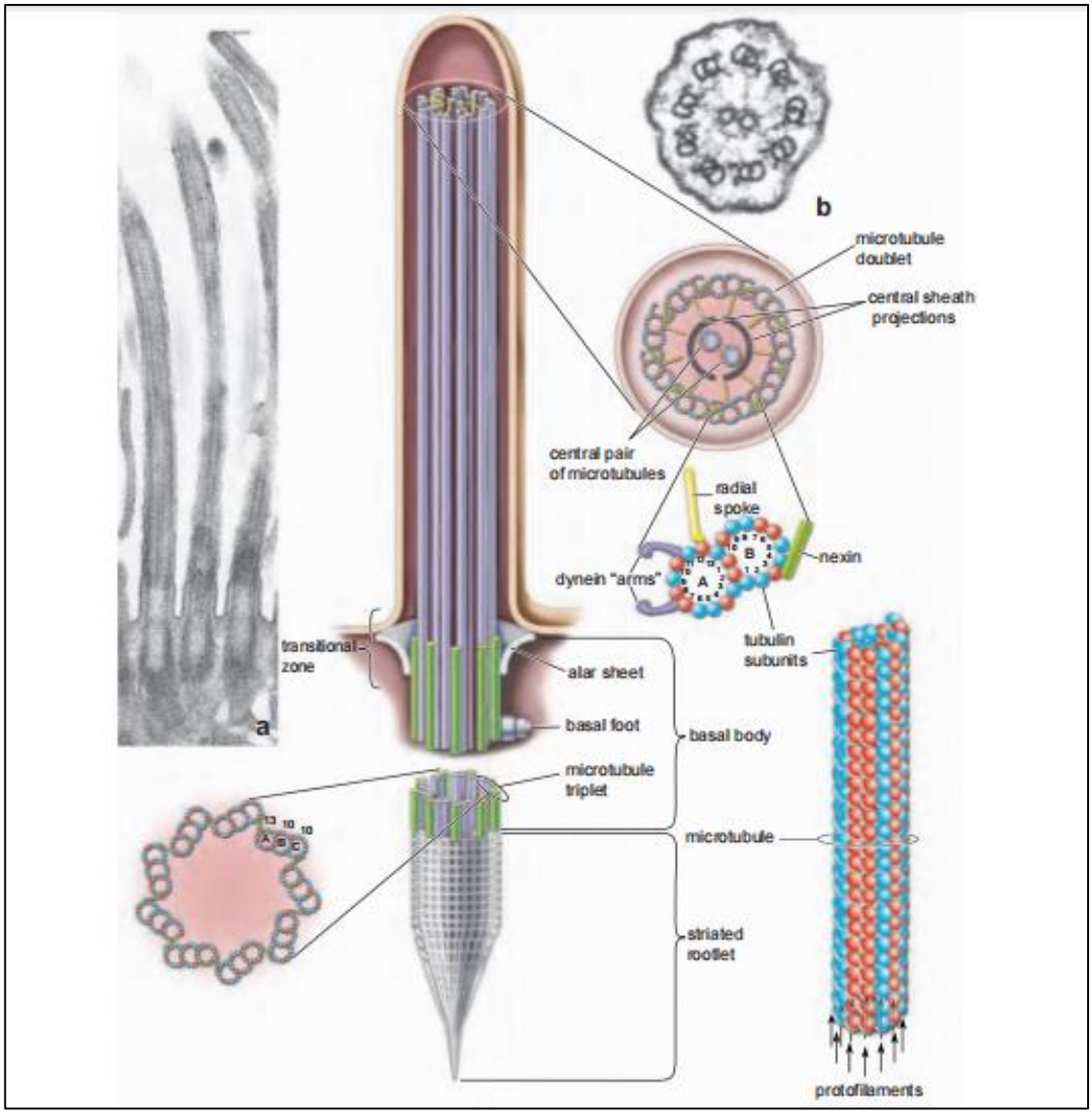

Molecular structure of cilia

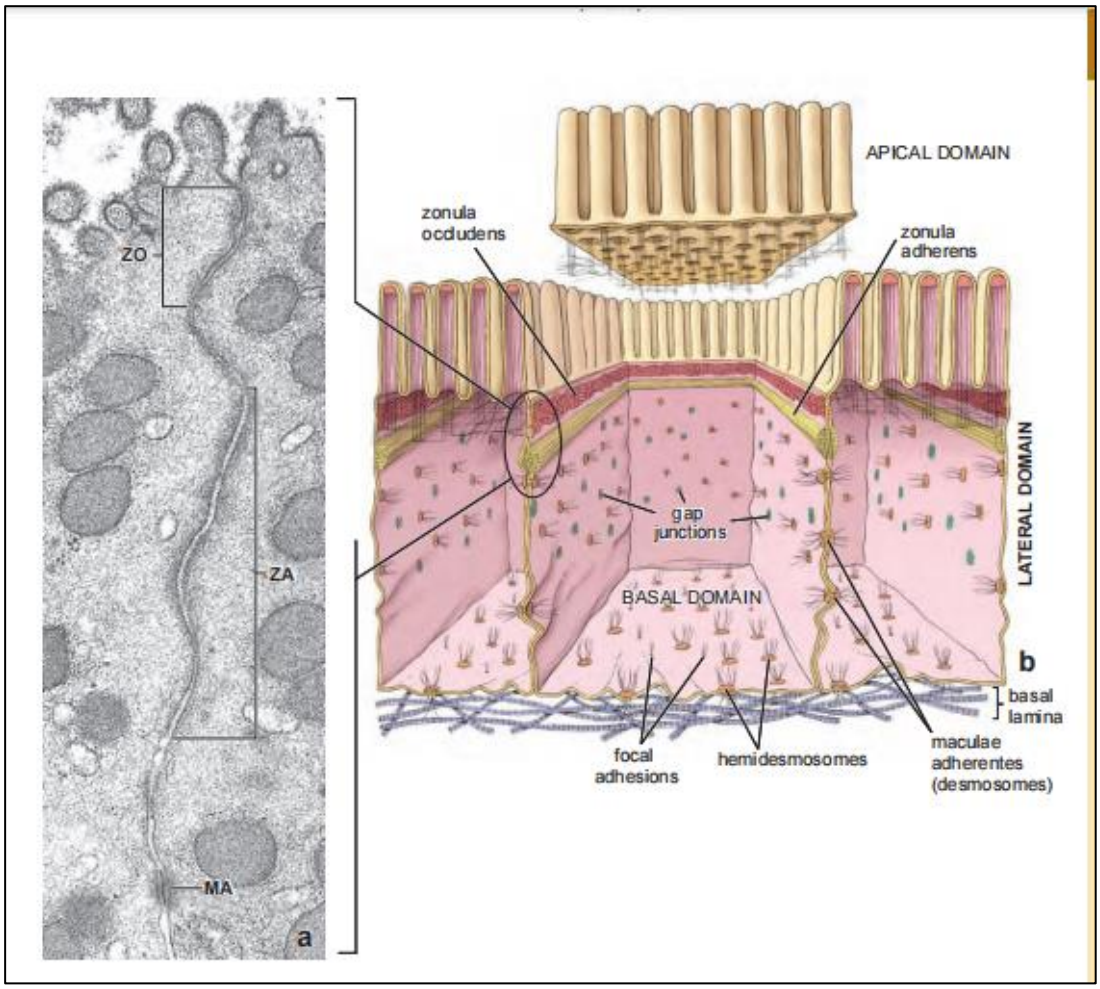

Junctional complex.

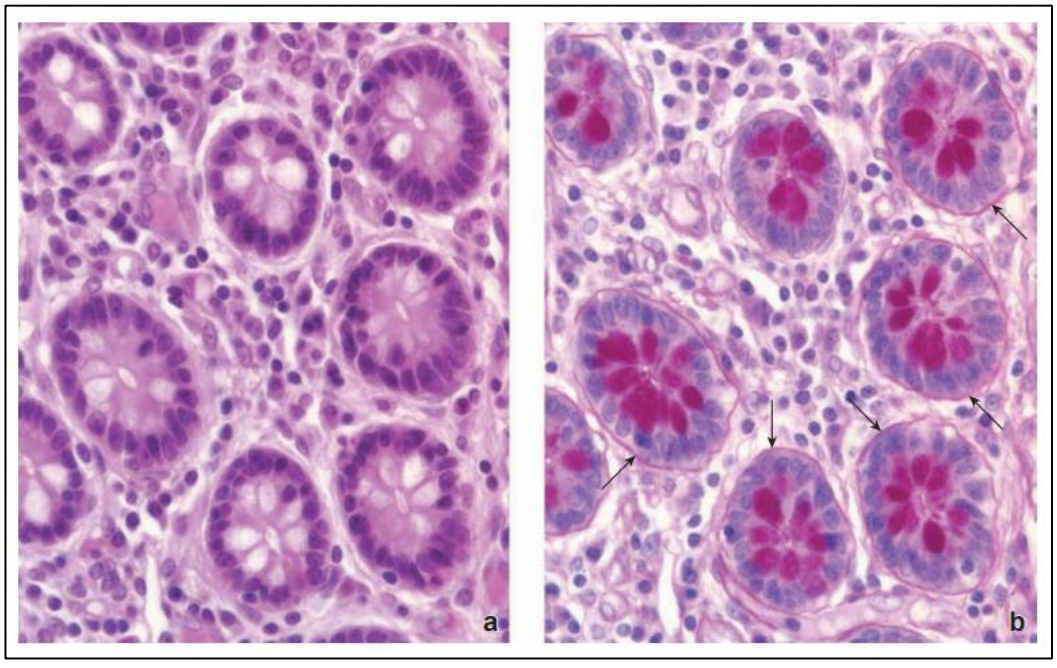

Photomicrographs showing serial sections of intestinal glands of the colon.

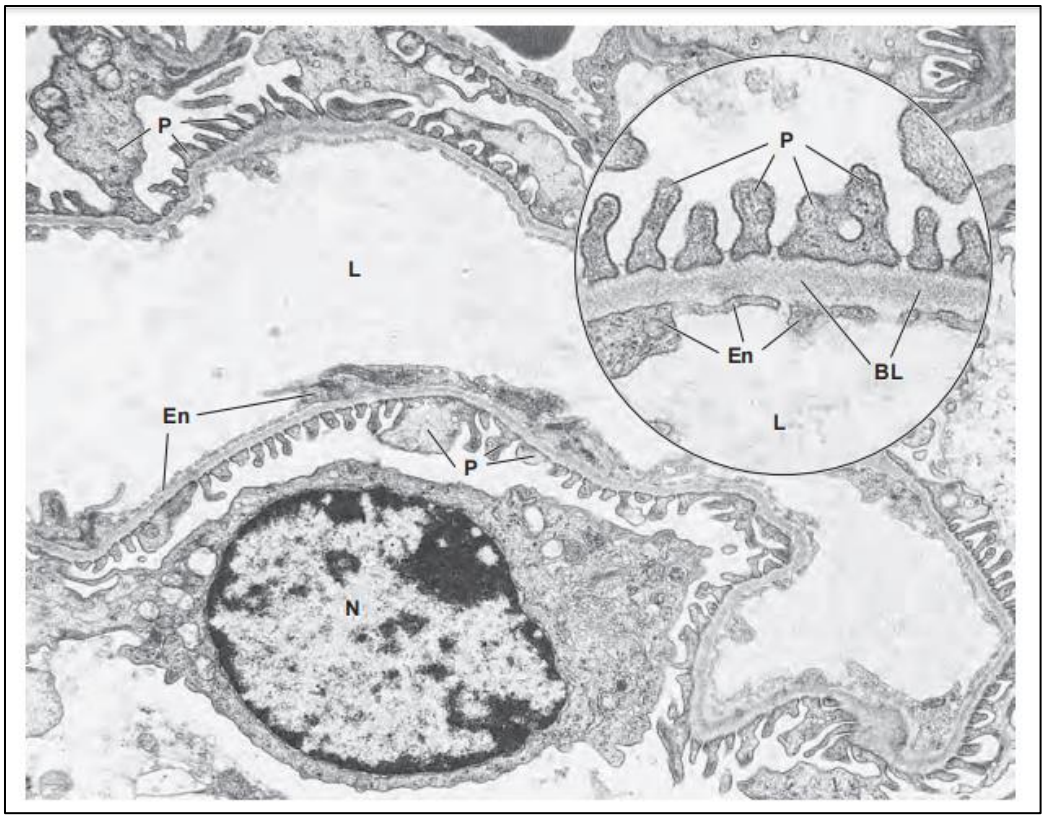

Basal lamina in the kidney glomerulus.

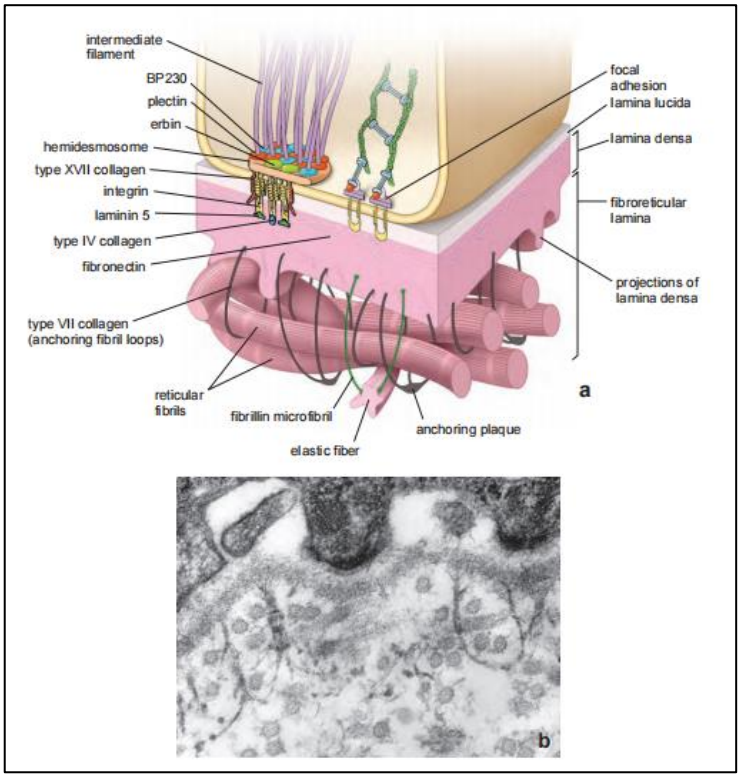

Schematic diagram and electron micrograph of the basal portion of epithelial cell.

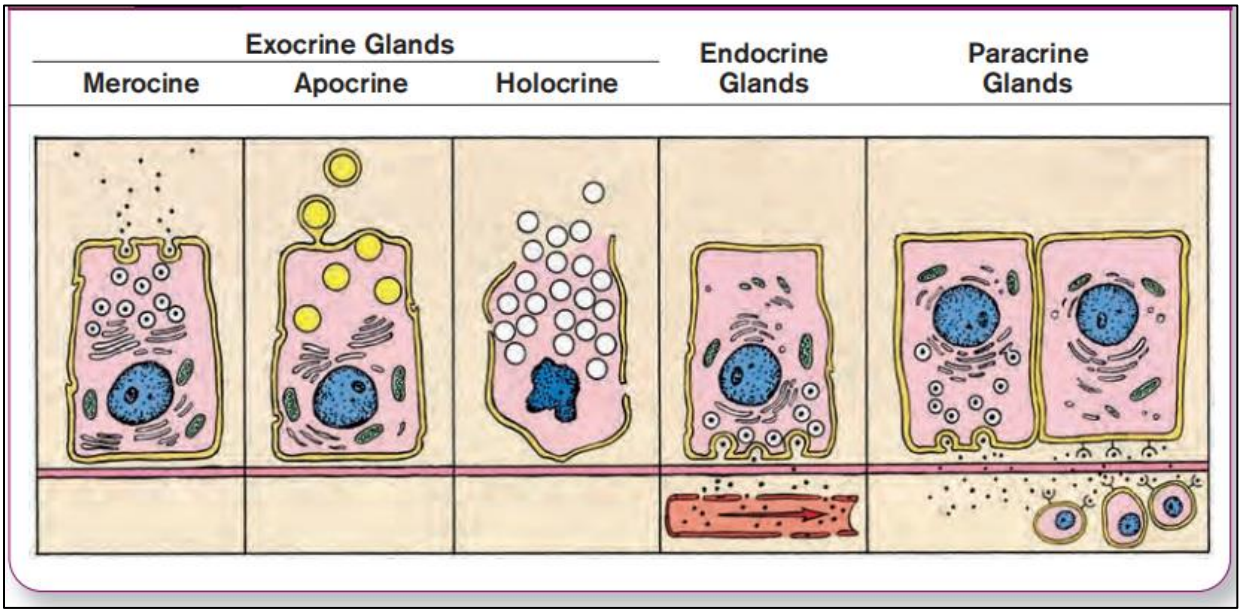

Different types of glands.

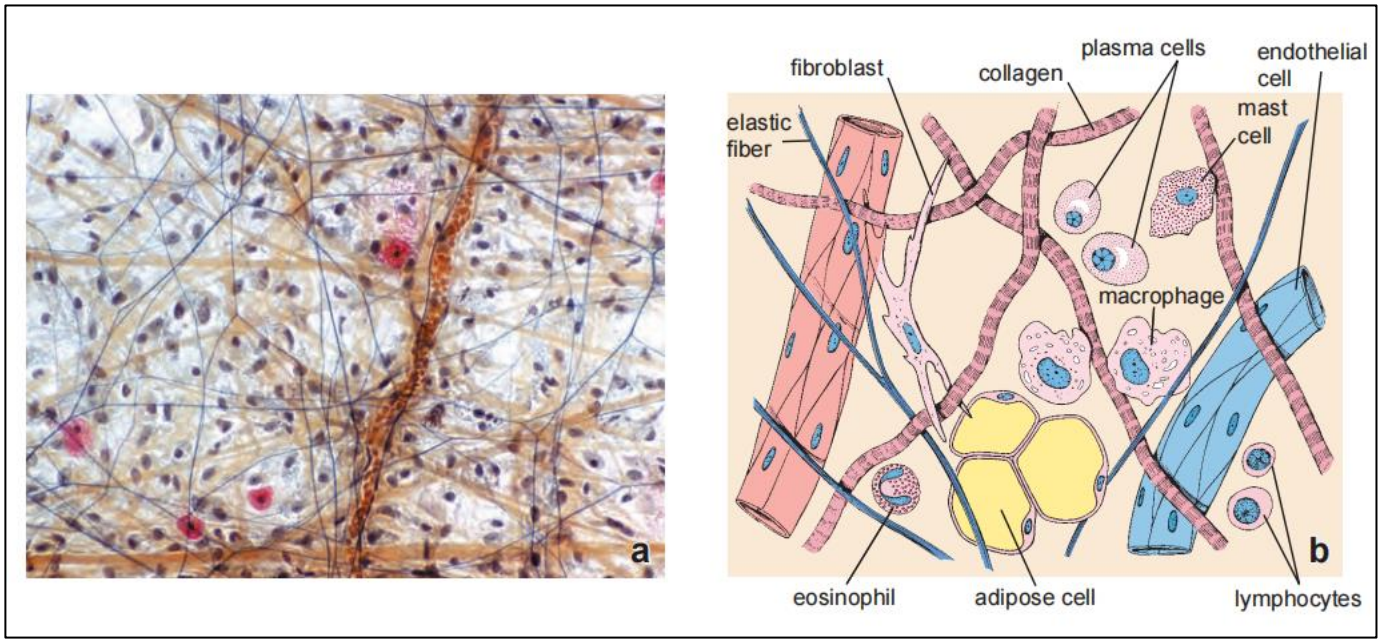

Loose connective tissue.

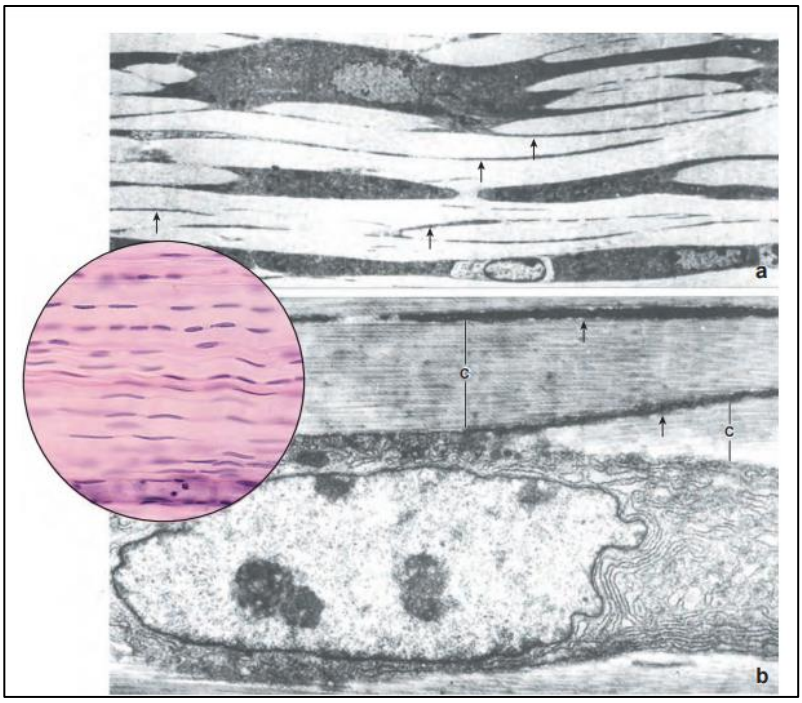

Dense regular connective tissue—tendon.

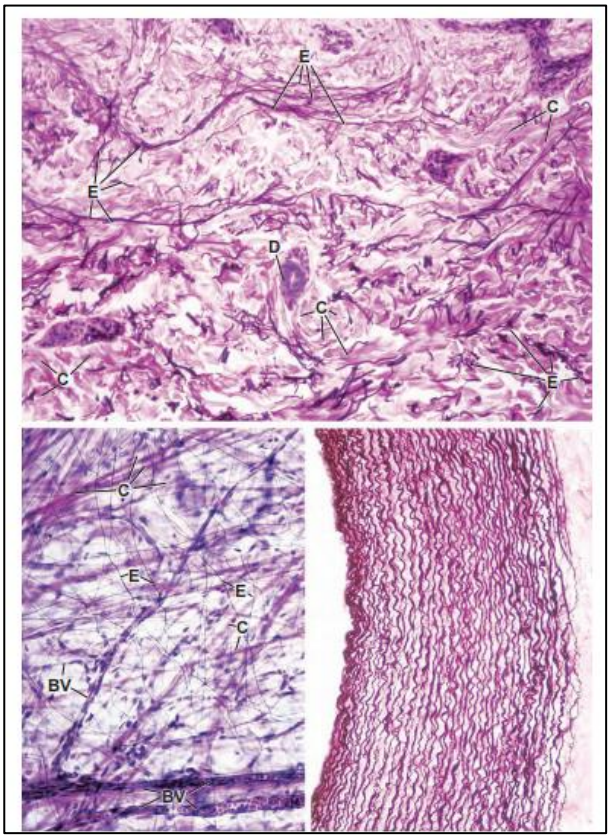

Photomicrograph of elastic fibres.

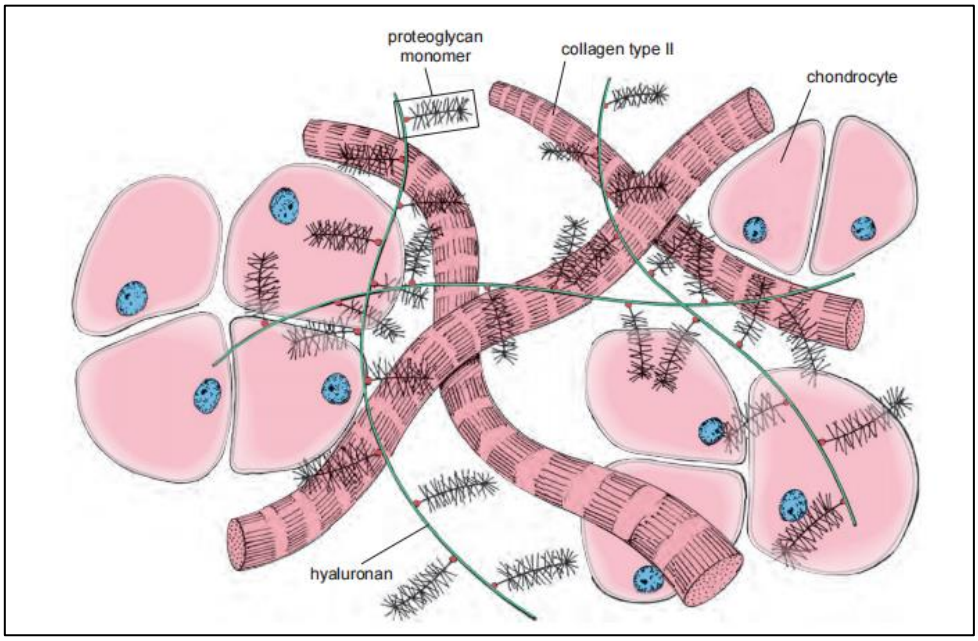

Molecular structure of hyaline cartilage matrix.

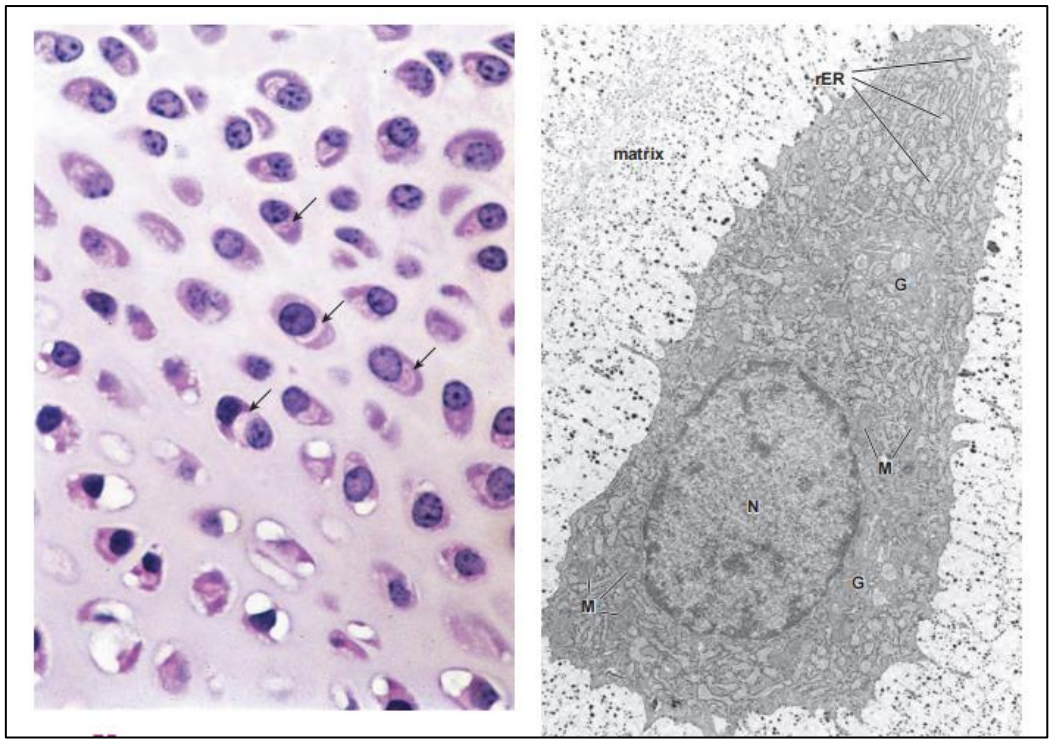

Growing young, active chondrocyte and surrounding matrix.

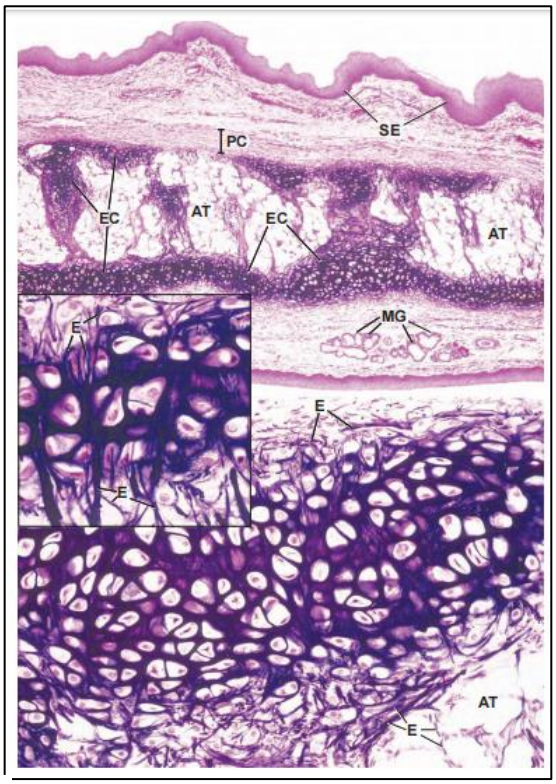

Photomicrograph of an elastc cartilage.

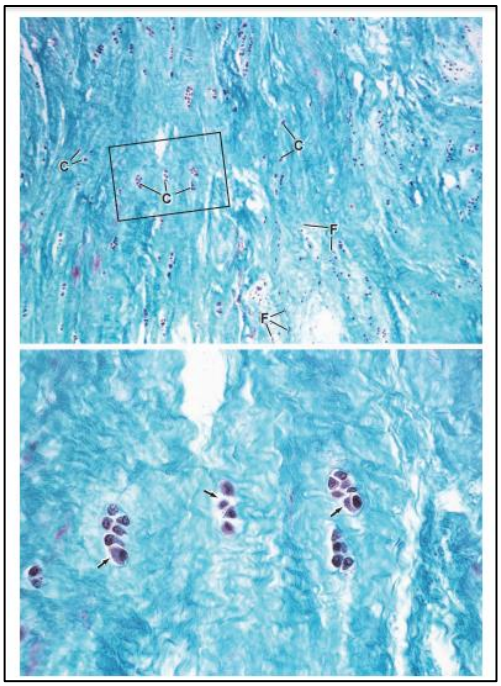

Photomicrograph of a fibro cartilage.

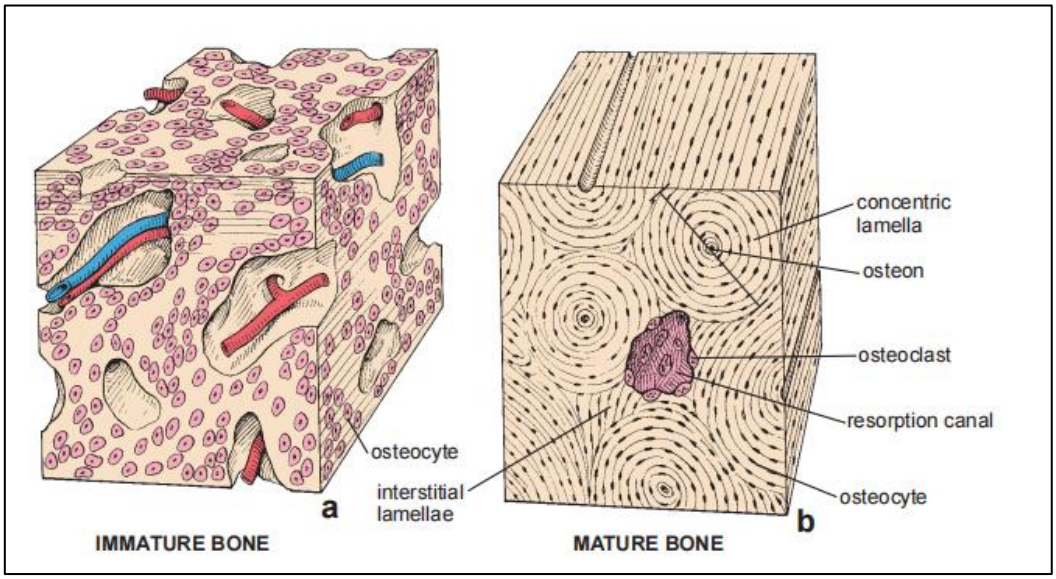

Diagram of immature and mature bone.

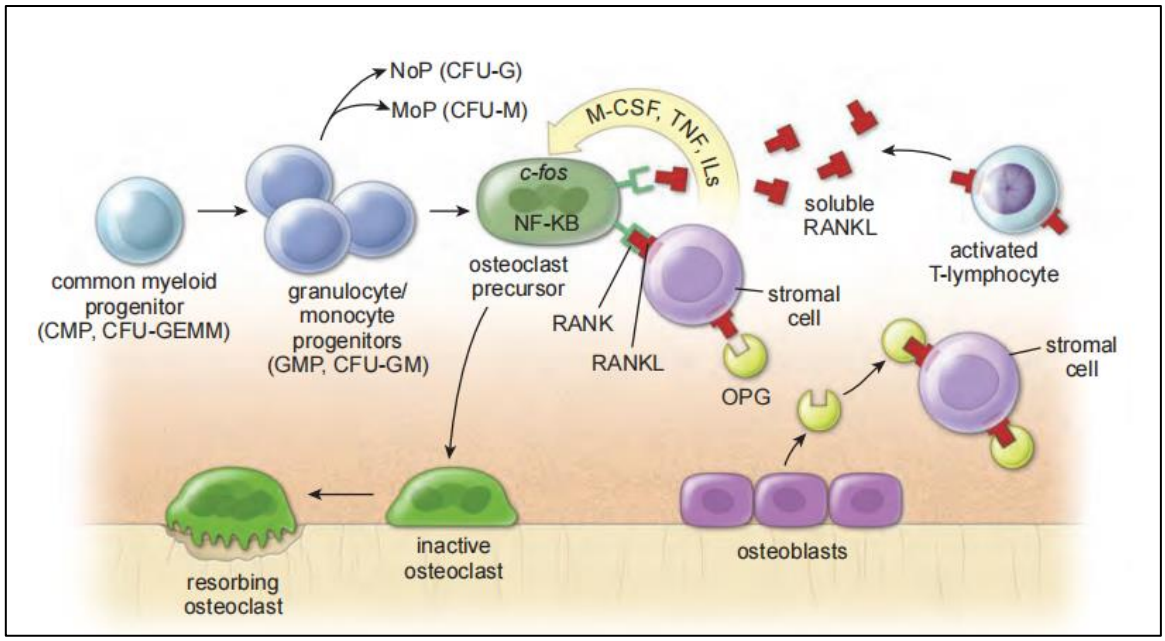

Schematic diagram of origin of osteoclasts.

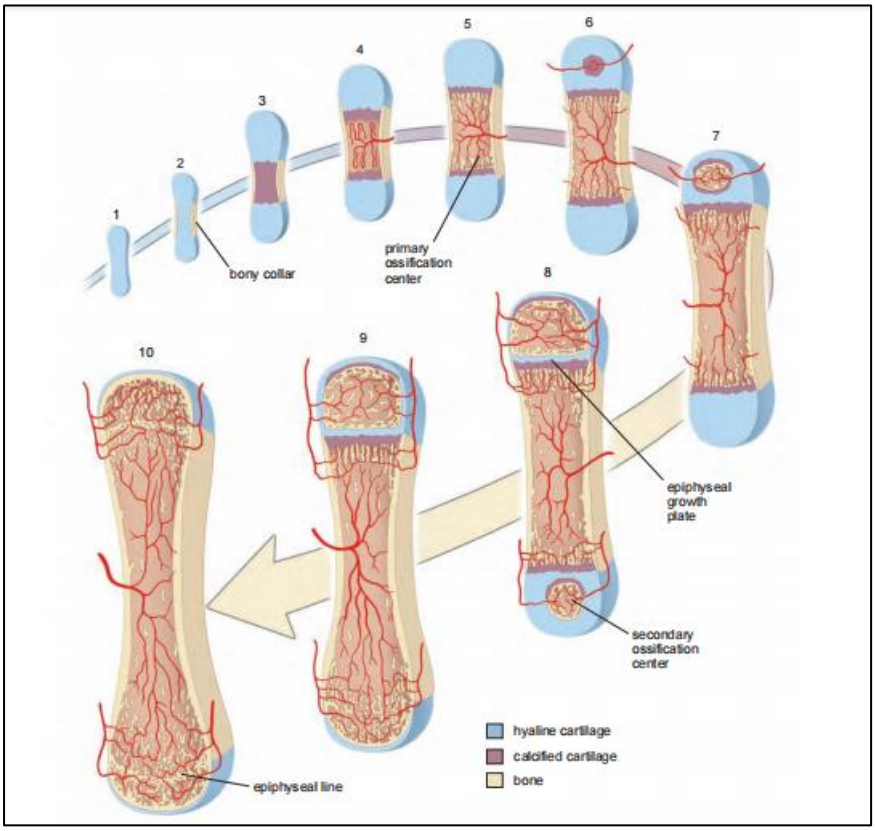

Schematic diagram of developing long bone.

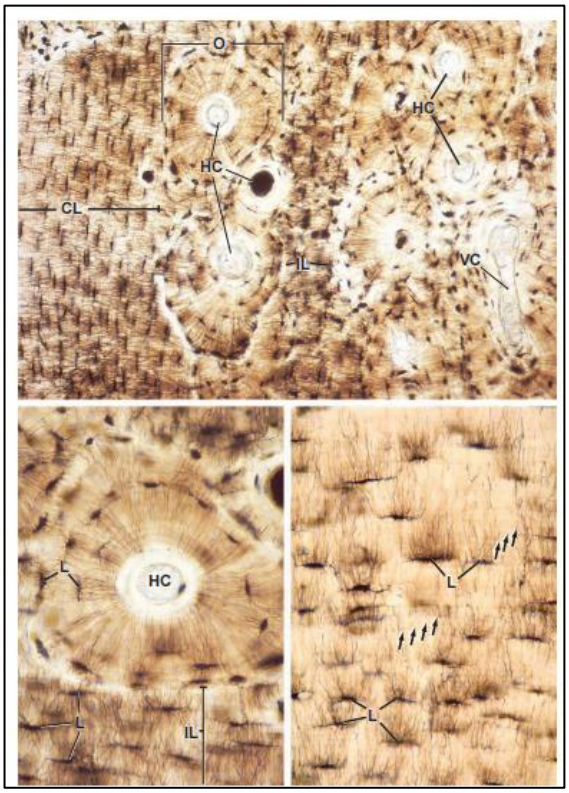

Ground section of a bone.

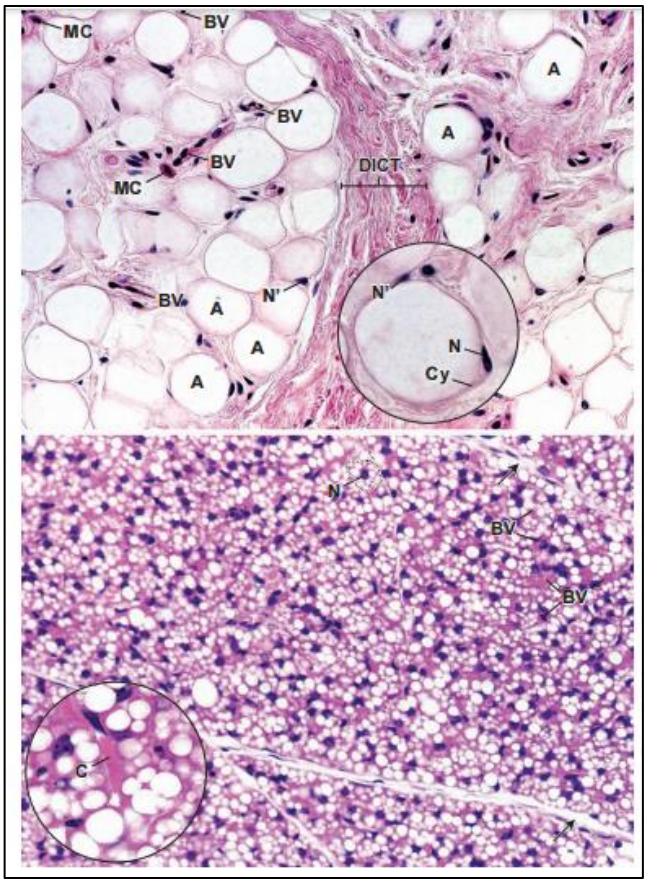

Photomicrograph of brown and white adipocytes.

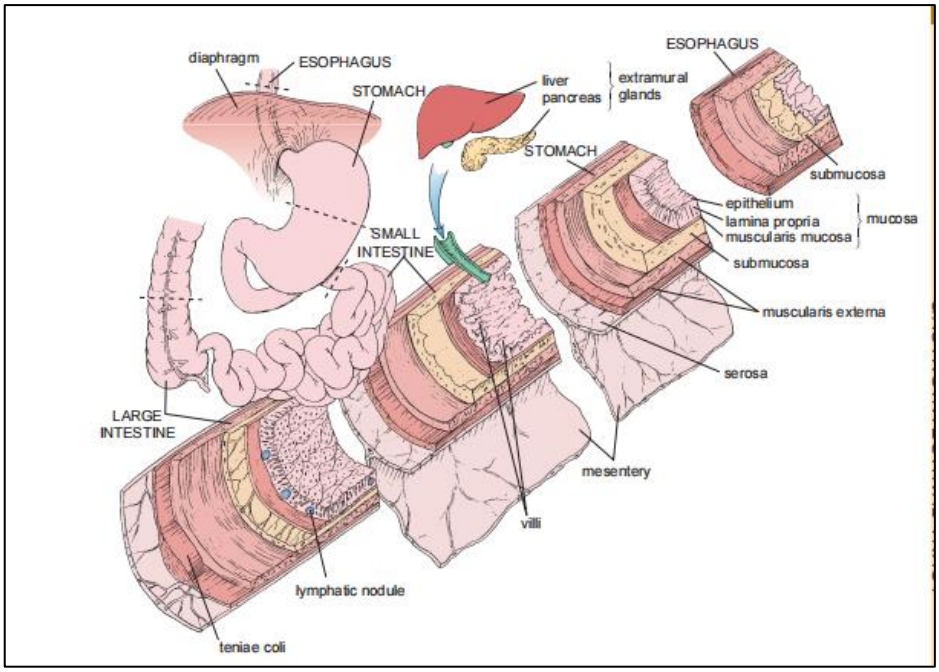

Diagram of general organization of the alimentary canal.

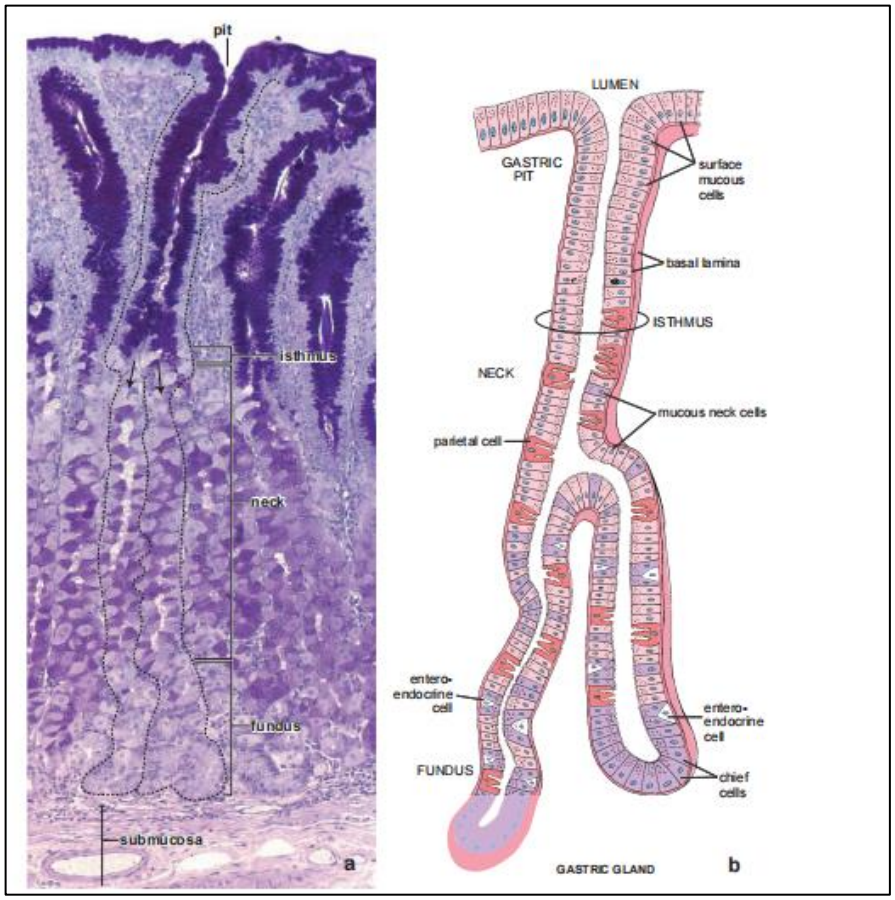

Diagram of a gastric glands.

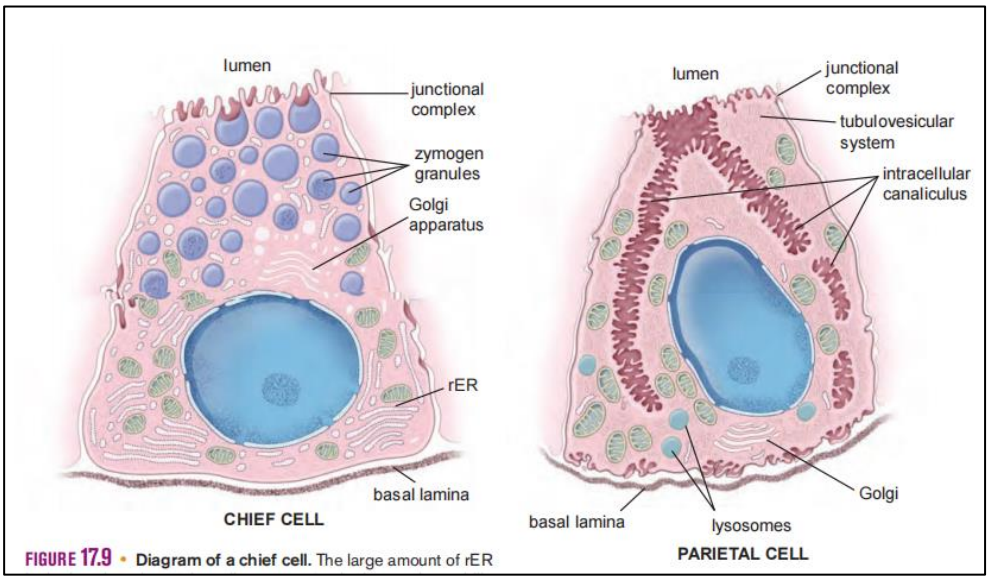

FIGURE 17.9 • **Diagram of a chief cell.** The large amount of rER

Diagram of a chief and parietal cells

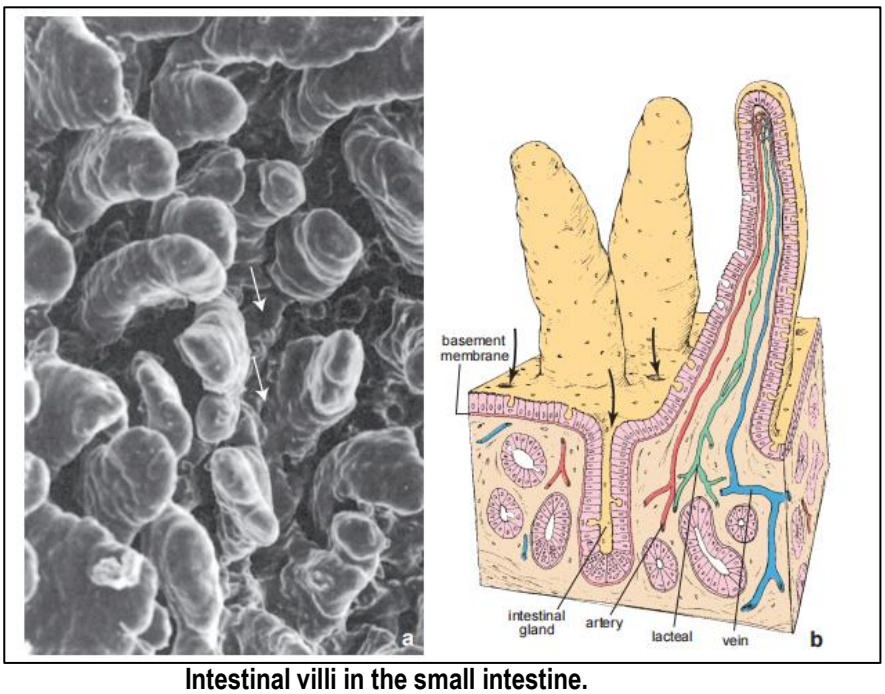

Intestinal villi in the small intestine.

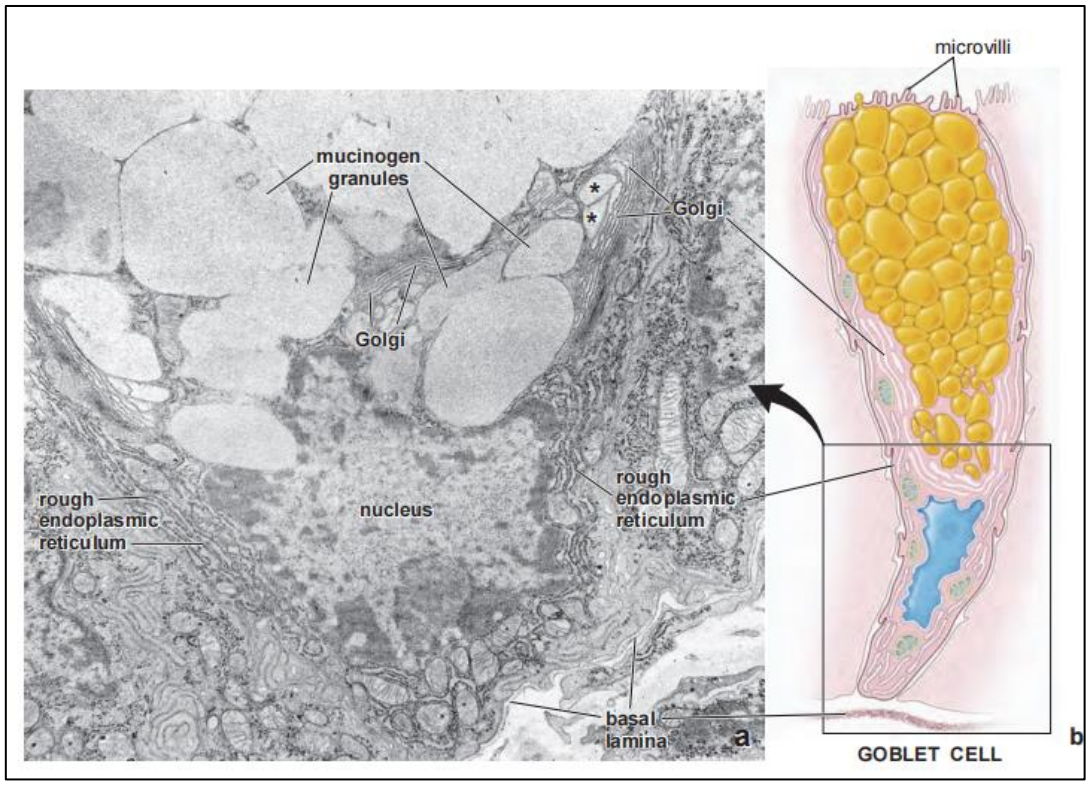

Diagram of a goblet cell.

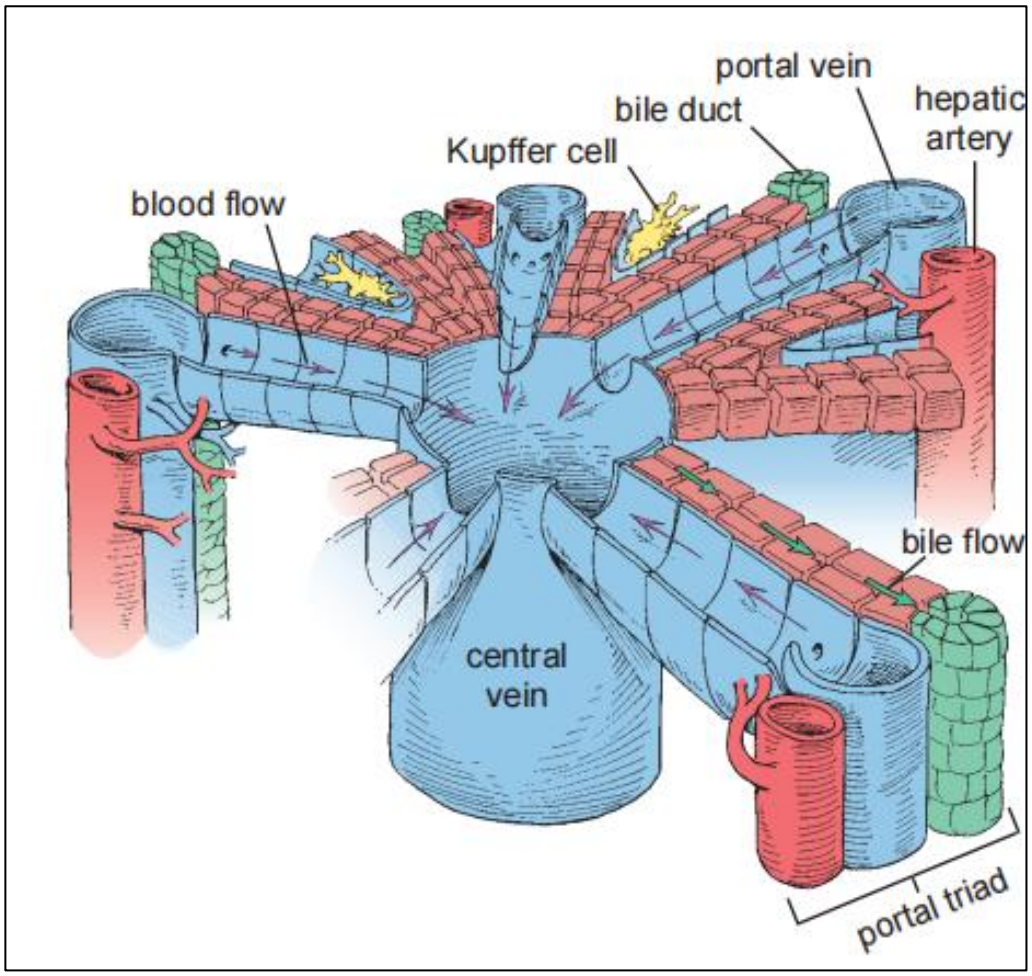

Diagram of the flow of blood and bile in the liver.



Hepatocyte ultrastructure and major functions.

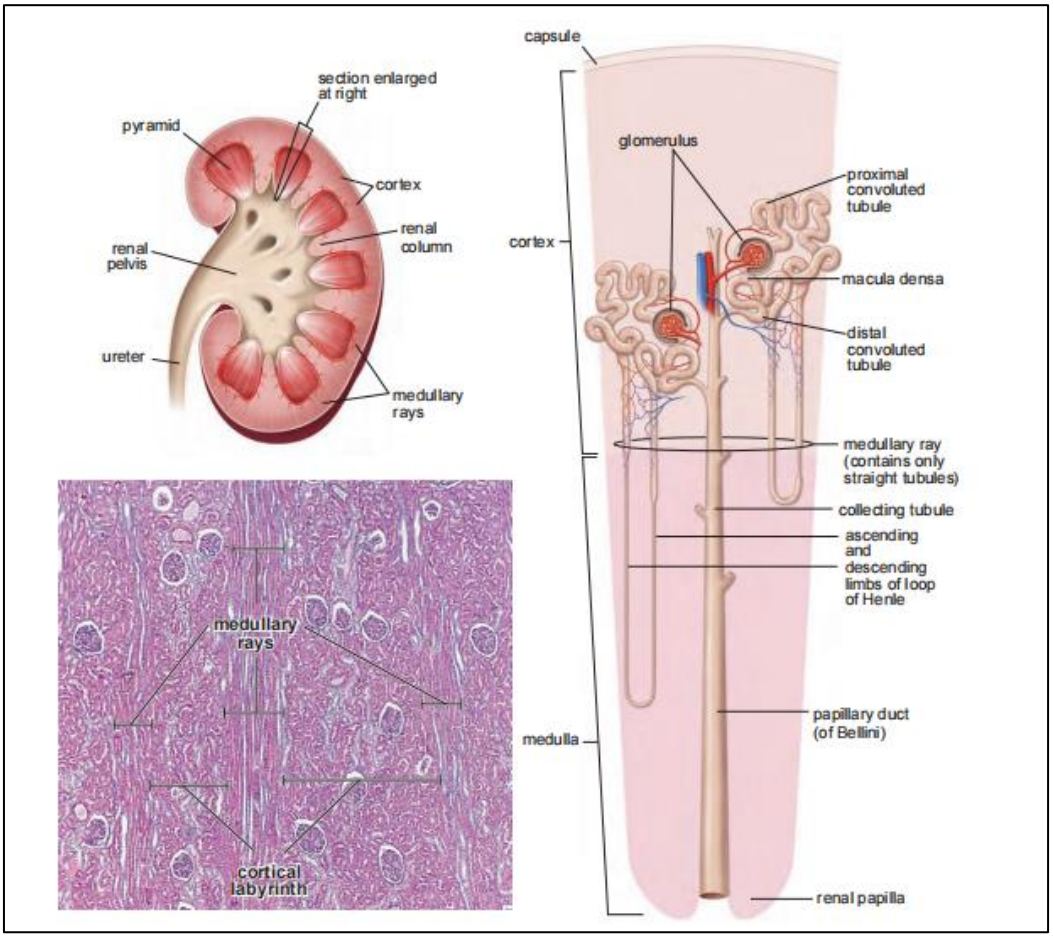

Diagrams and photomicrograph of an adult human kidney.

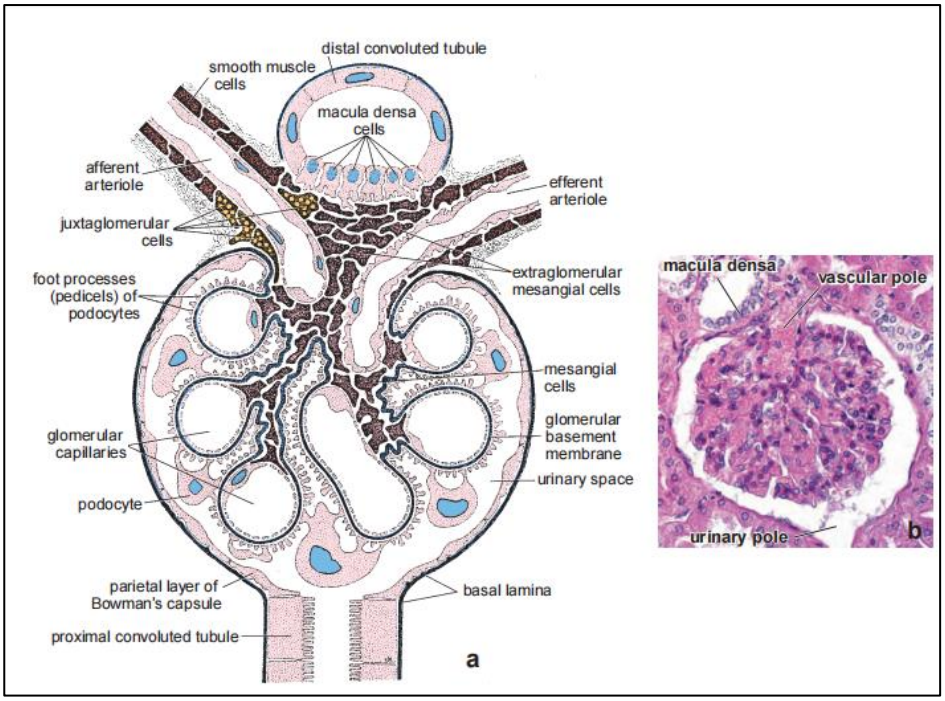

Structure of the renal corpuscle.

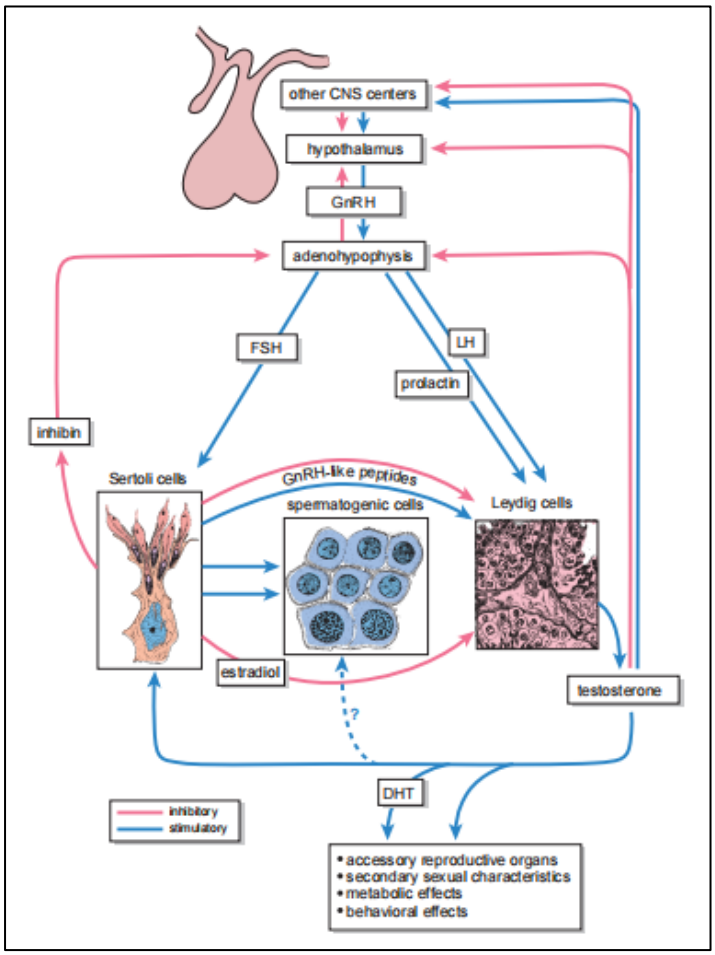

Diagram depicting the hormonal regulation of male reproductive function.

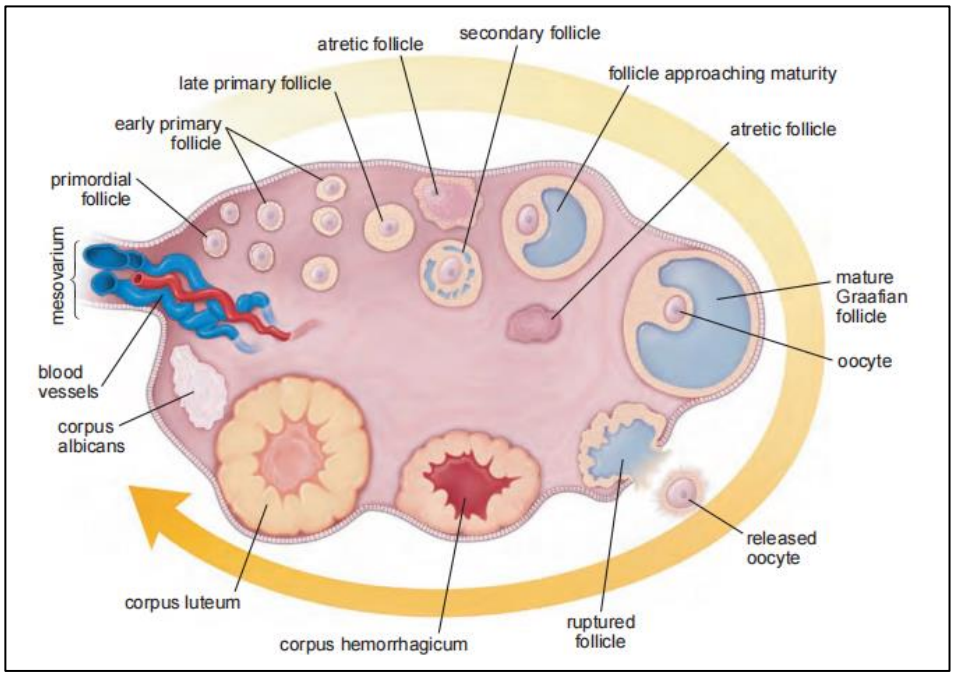

Schematic drawing of a section through the ovary.

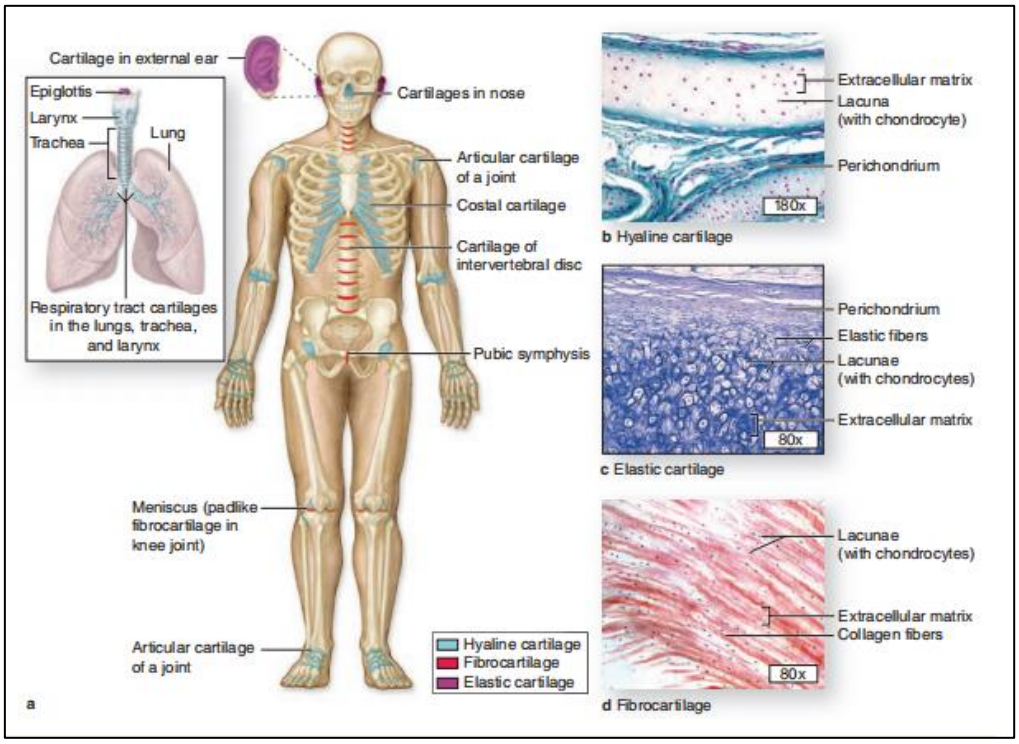

Distribution of cartilage in adults.

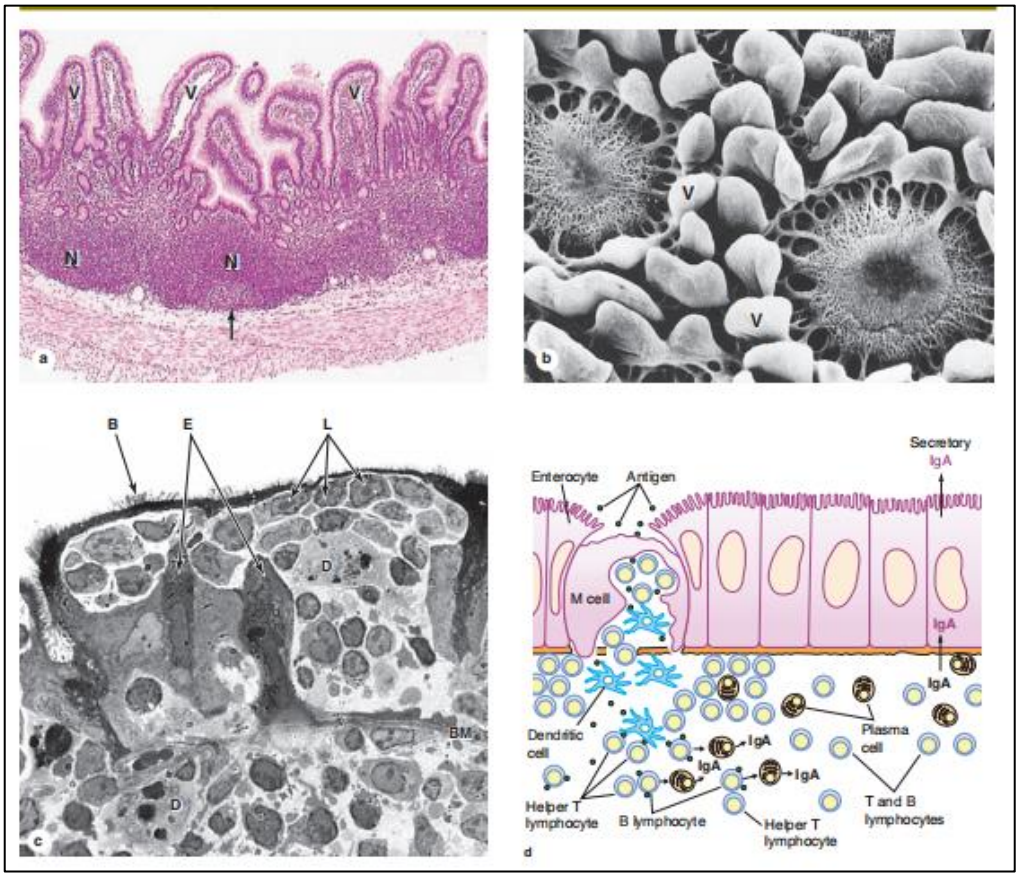

Diagram of Peyer's patch and M cells.

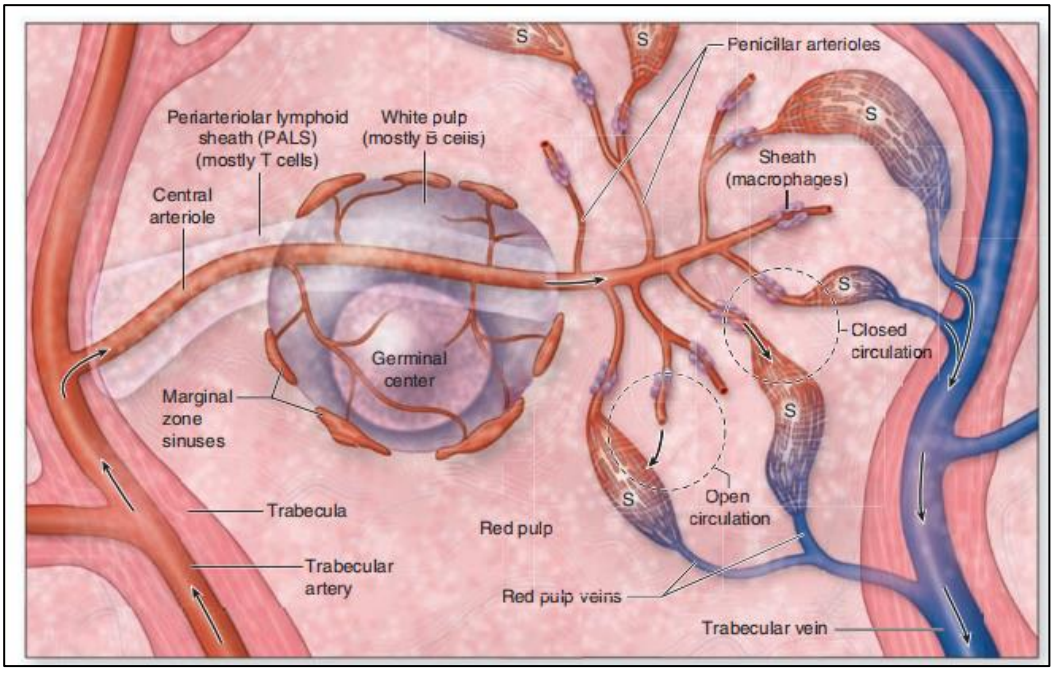

Diagram of open and closed circulation in the spleen.

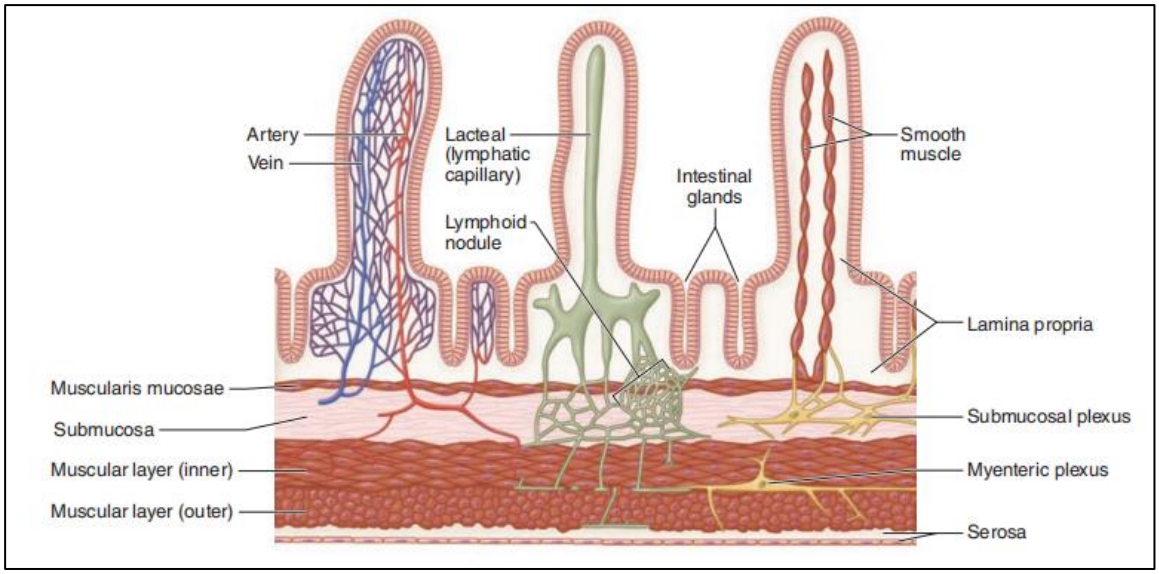

Microvasculature, lymphatics, and muscle in villi.

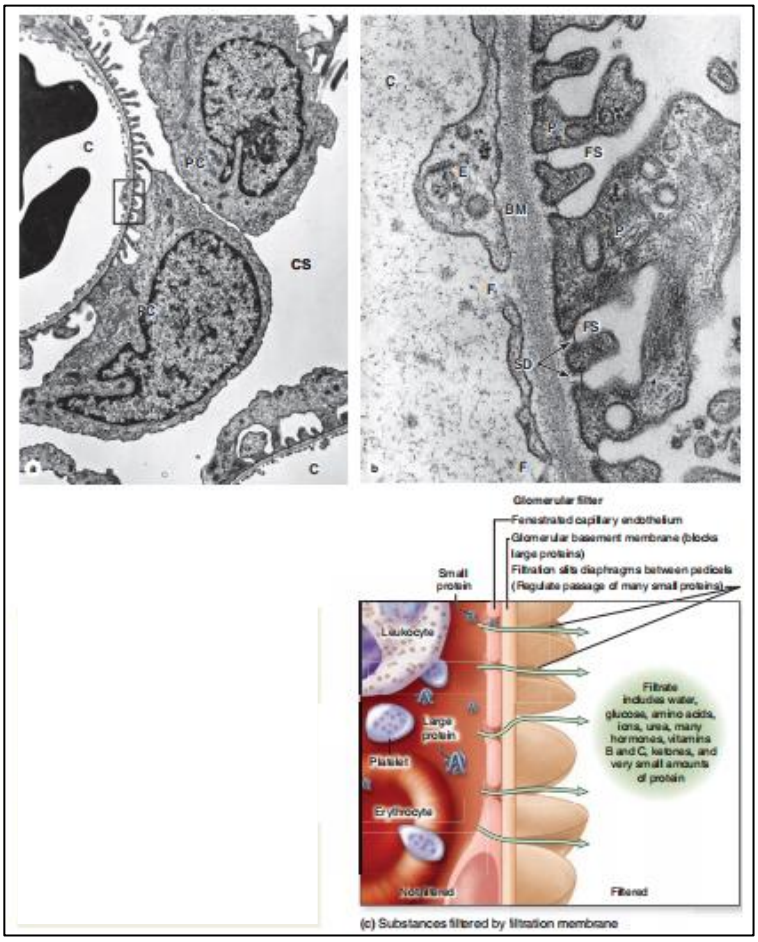

Diagram of Glomerular filtration barrier.

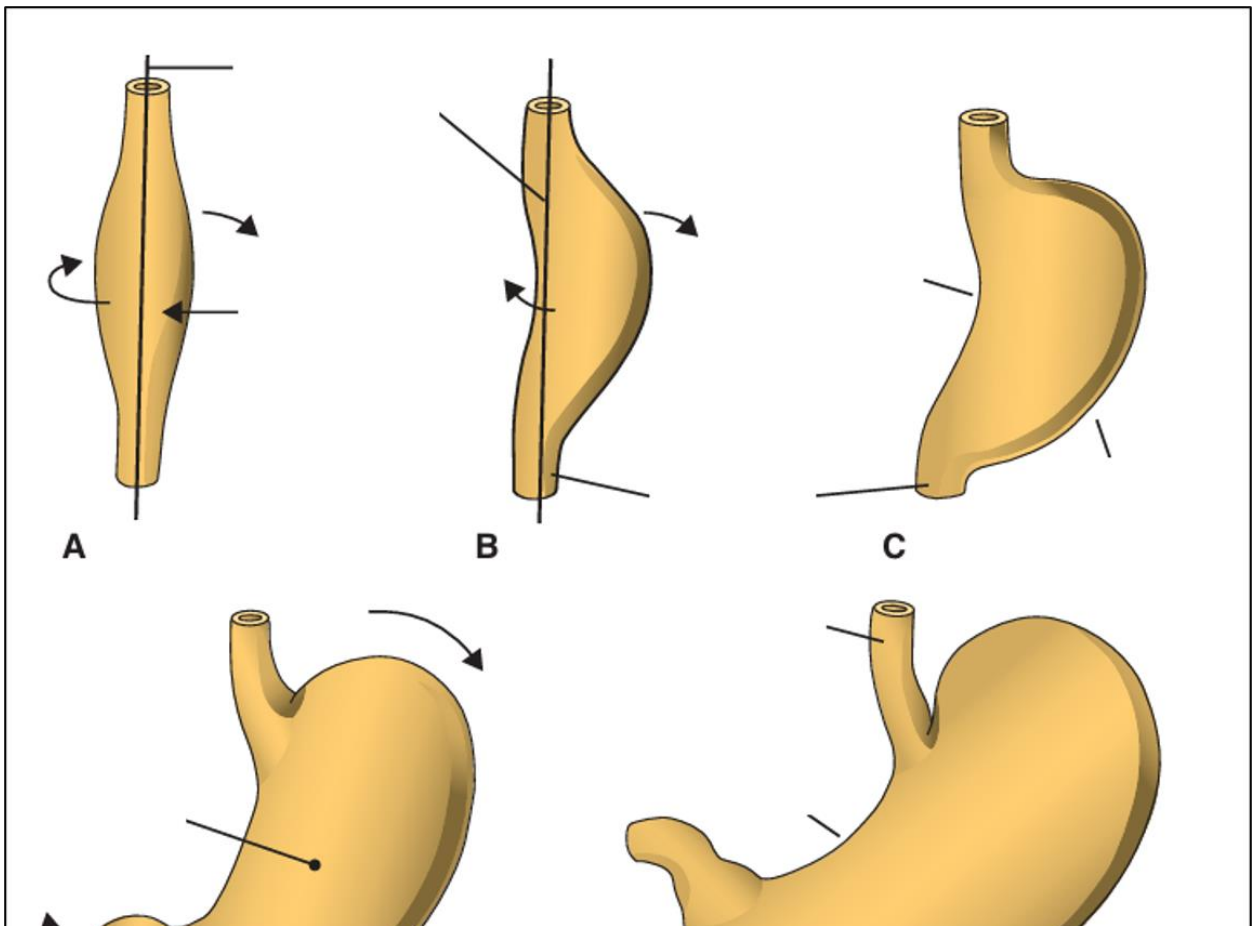

Developmental rotations of stomach.

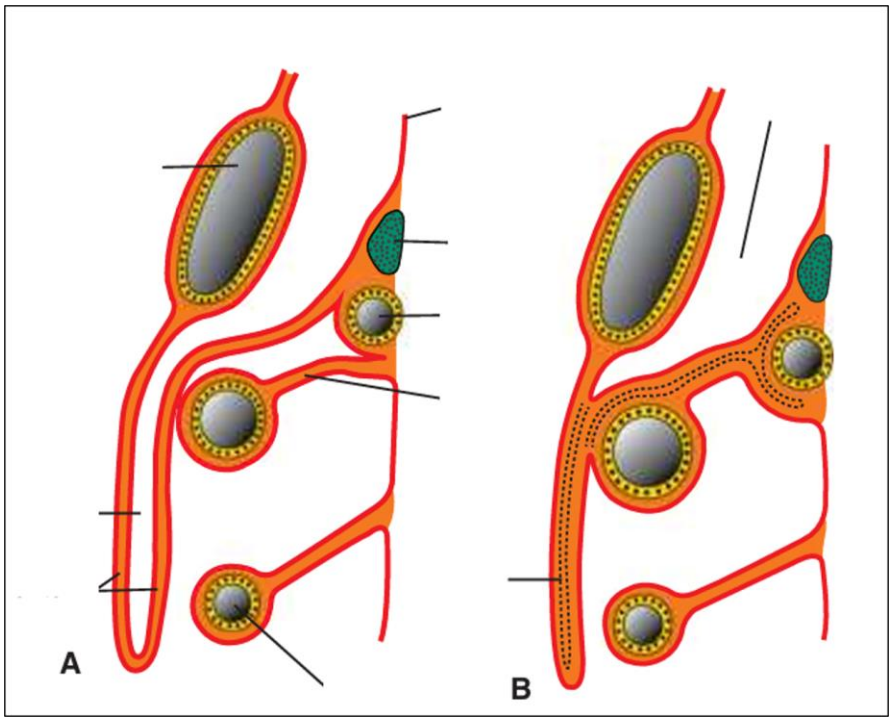

Sagittal section showing the relation of the greater omentum, stomach, transverse colon, and small intestinal loops at 4 months.

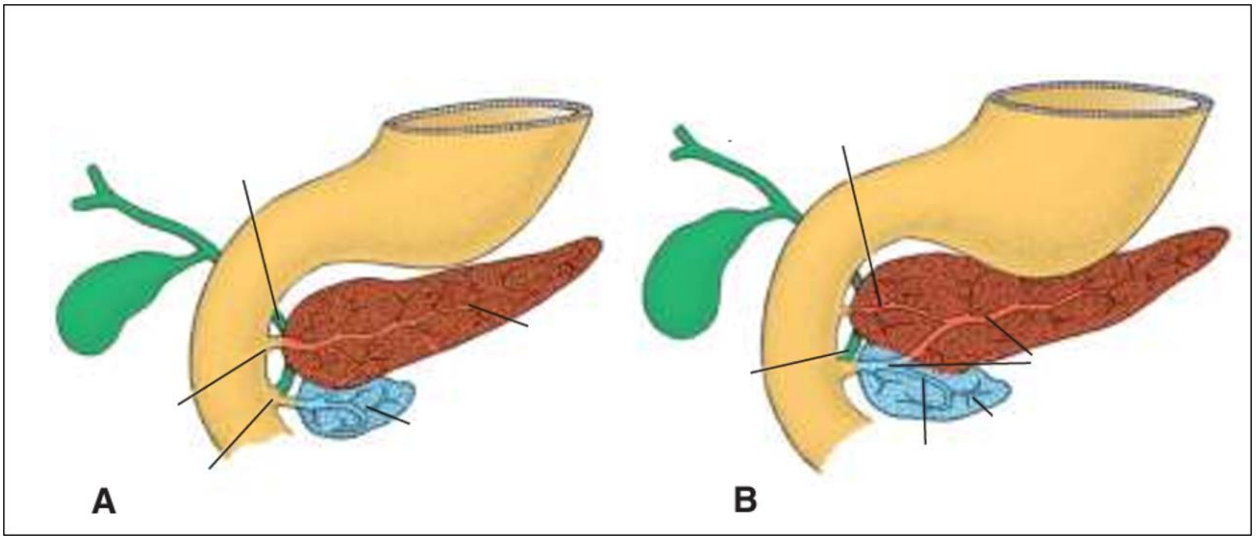

Development of the pancreas.

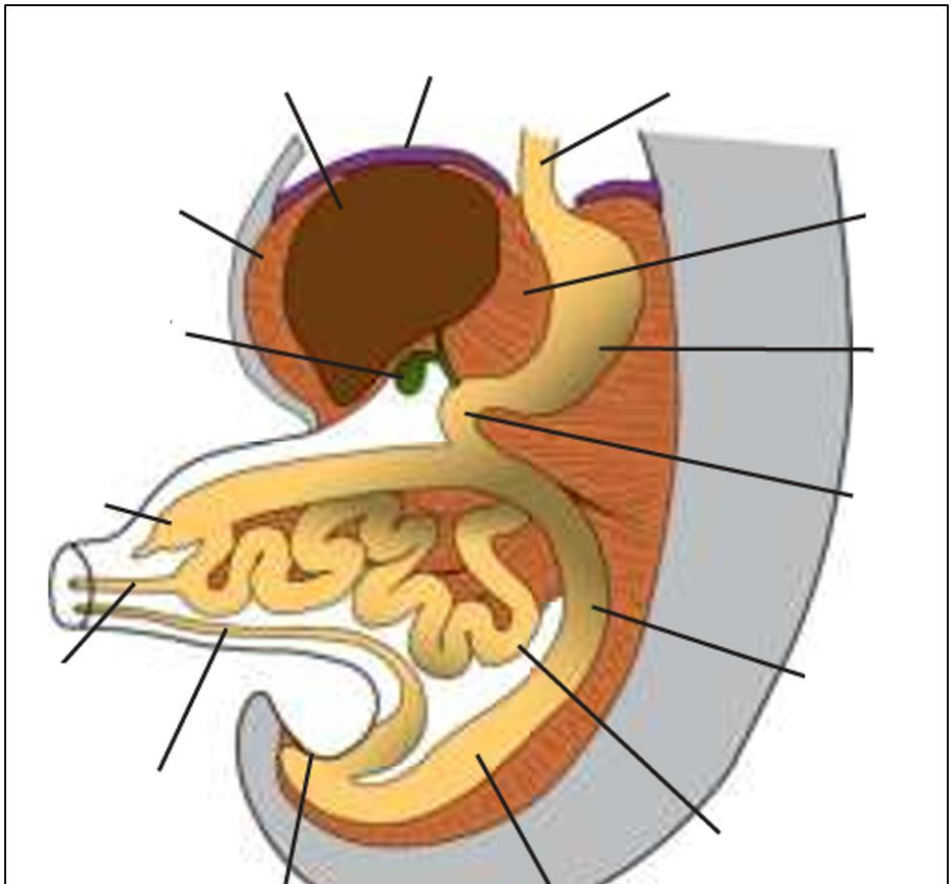

Umbilical herniation of the intestinal loops in an embryo of approximately 8 weeks.

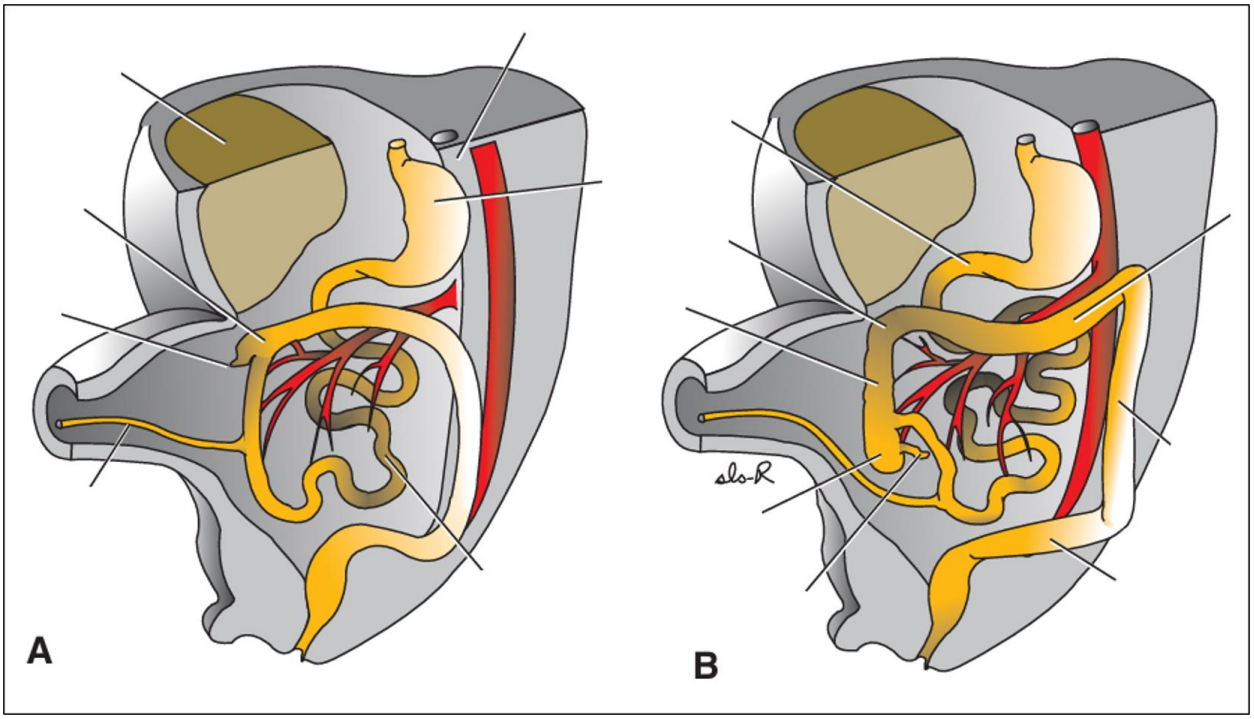

Developmental rotations of the midgut.



Developmental anomalies of the midgut / ventral body wall.

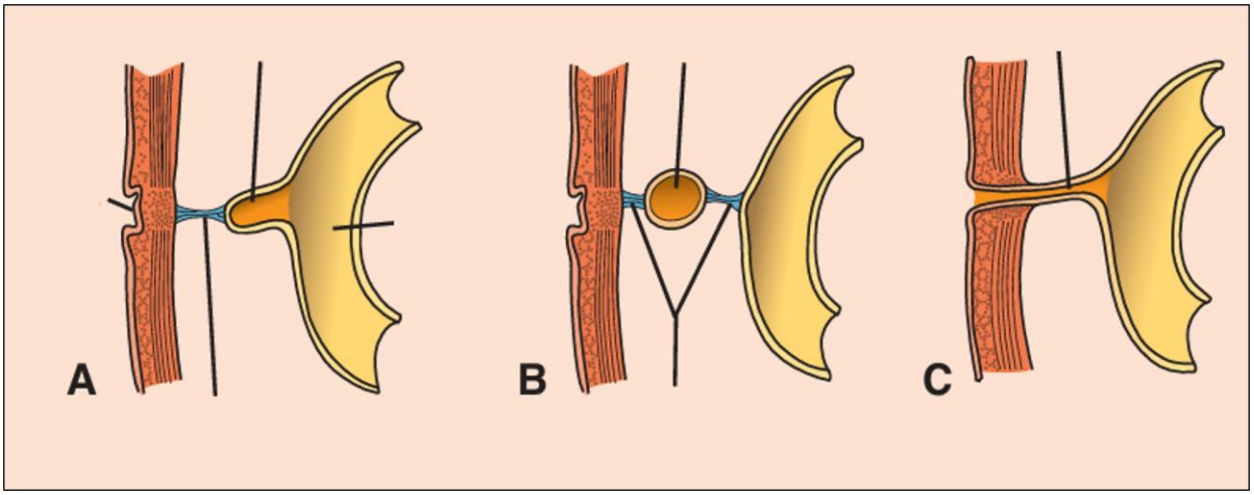

Ramnants of Vitelline duct.

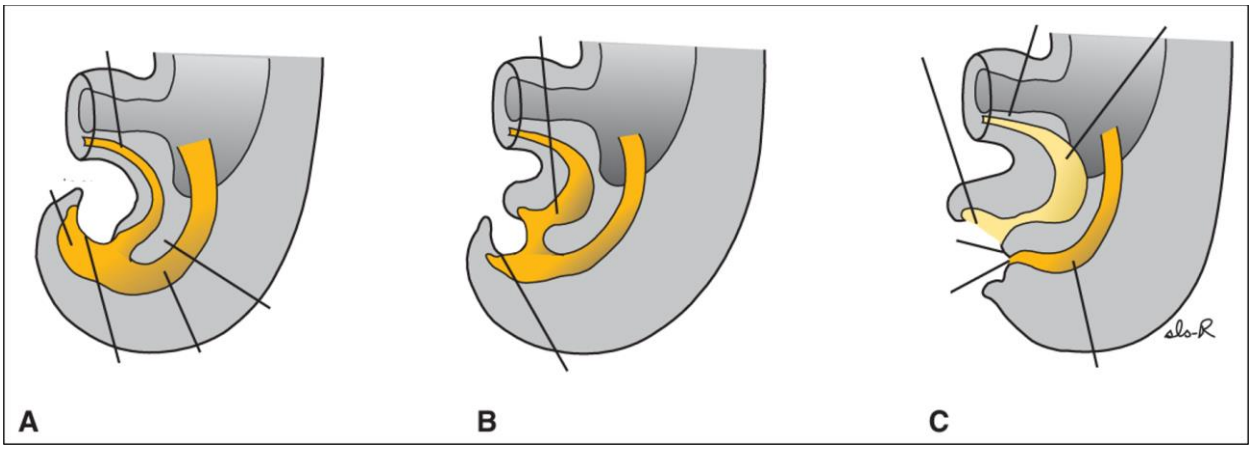

Cloacal region in embryos at successive stages of development.

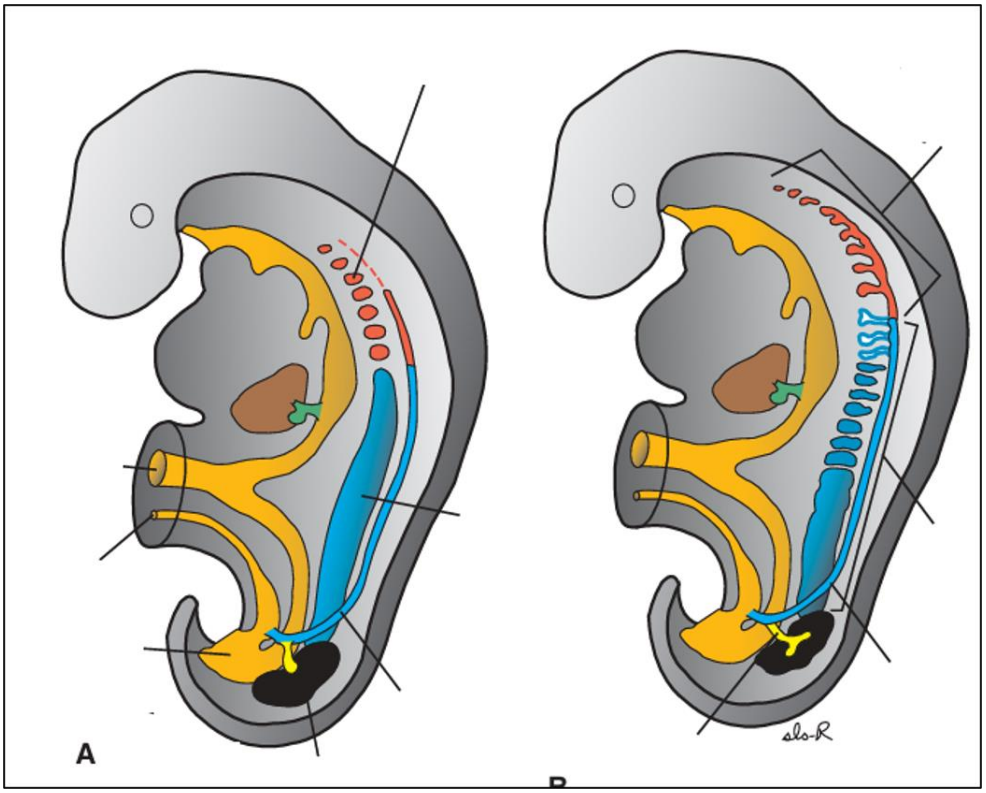

Relationship of the intermediate mesoderm of the pronephric, mesonephric, and metanephric systems

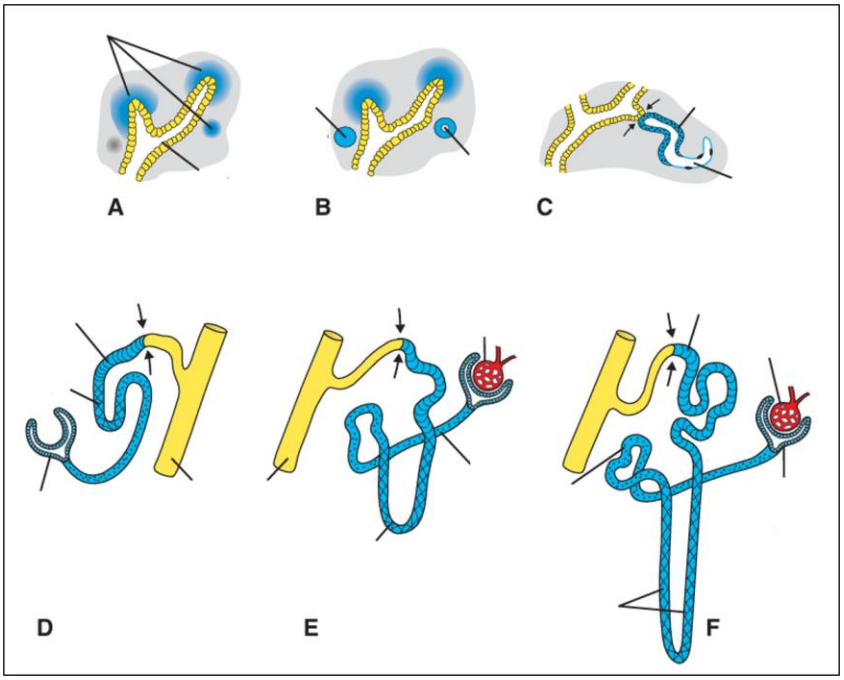

Development of a metanephric excretory unit.

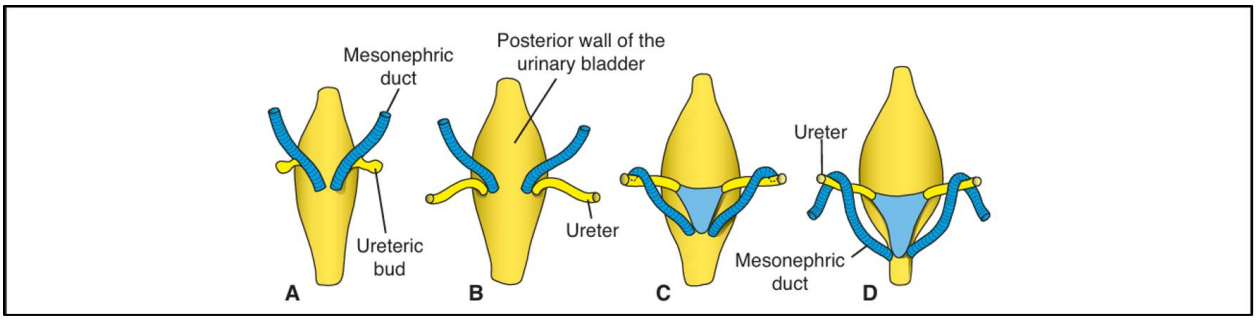

Dorsal view of the bladder showing its relationship with ureteric buds and mesonephric duct.

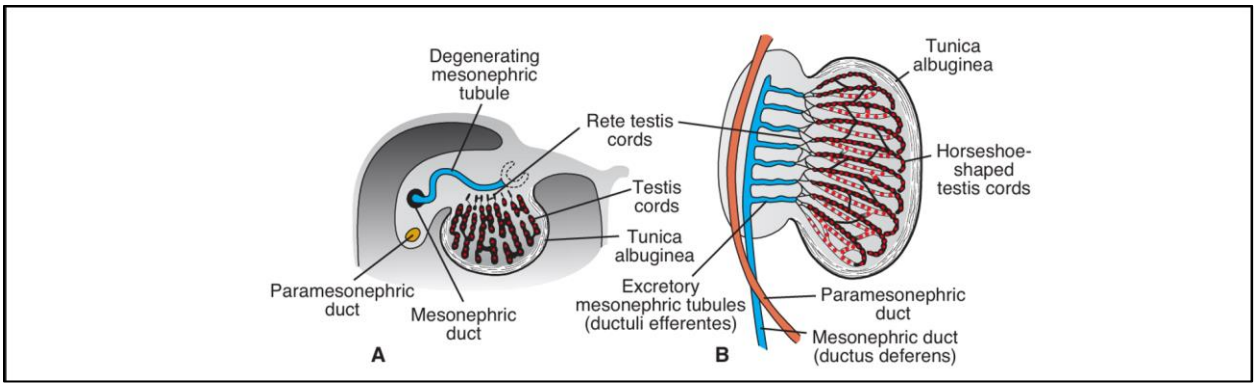

Transverse section through the testis in the eighth week, showing the tunica albuginea, testis cords, rete testis, and primordial germ cells. The glomerulus and Bowman's capsule of the mesonephric excretory tubule are degenerating.

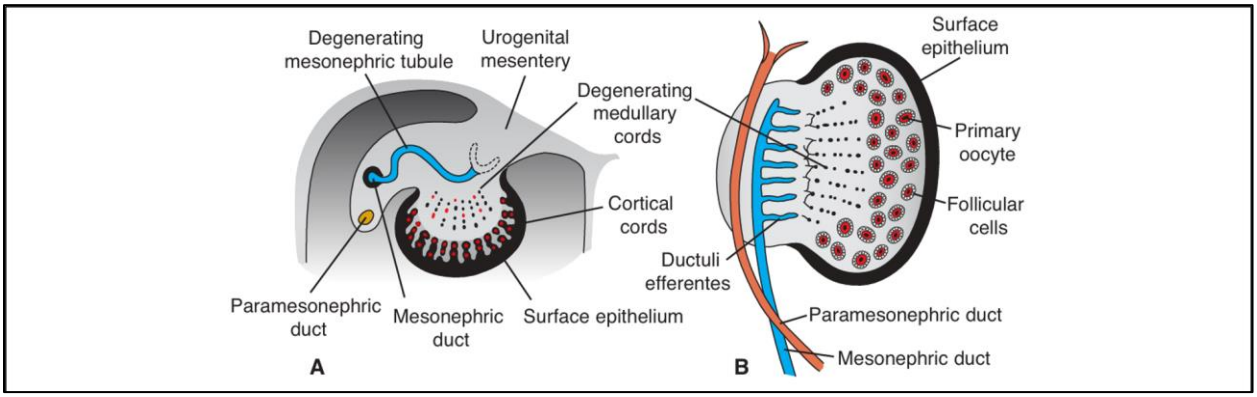

Transverse section of the ovary at the seventh week, showing degeneration of the primitive (medullary) sex cords and formation of the cortical cords.

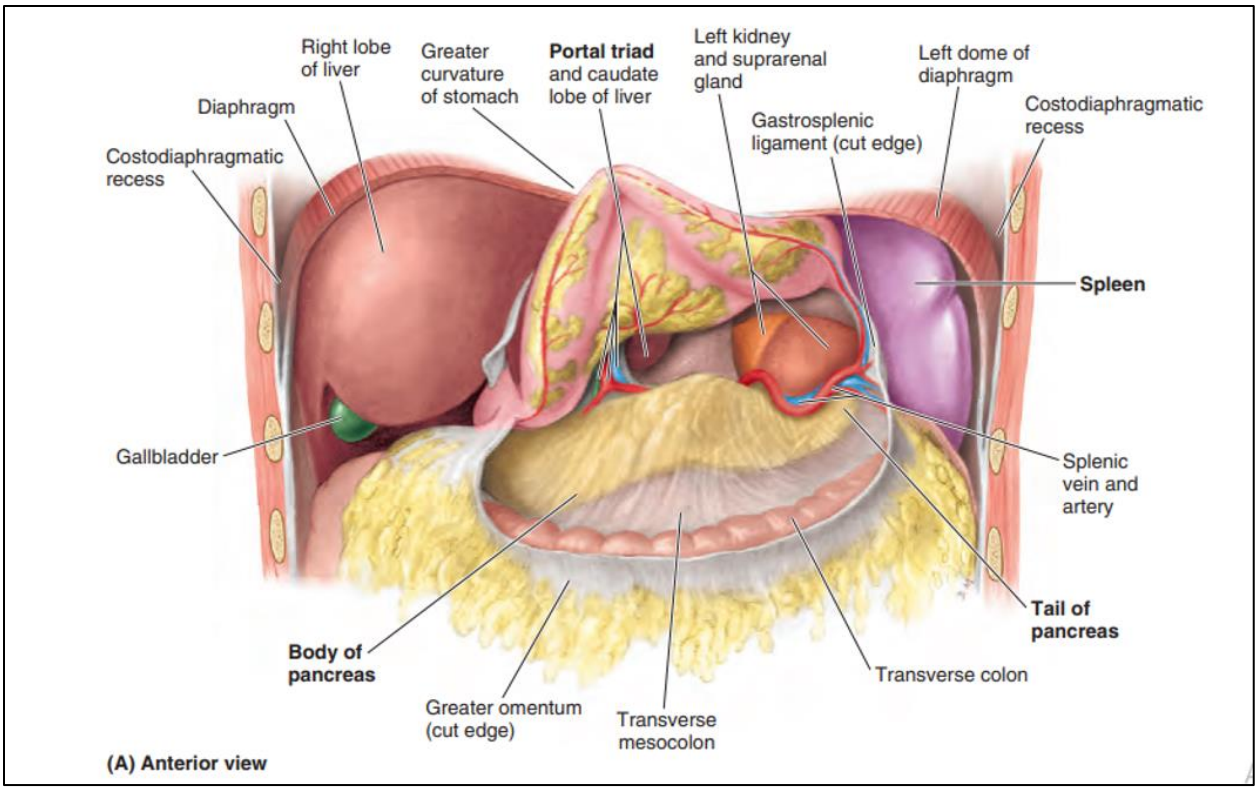

Relationships of Omental bursa and stomach bed

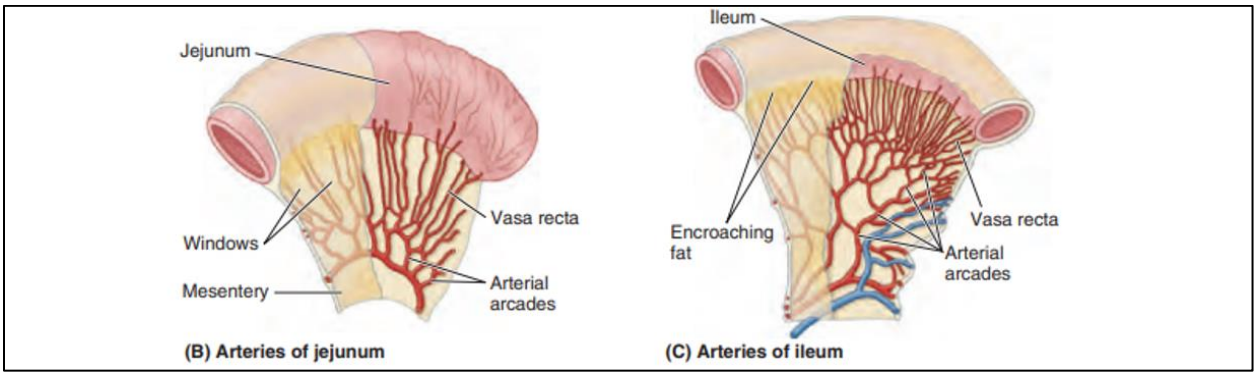

Mode of arterial supply to the jejunum and ileum.

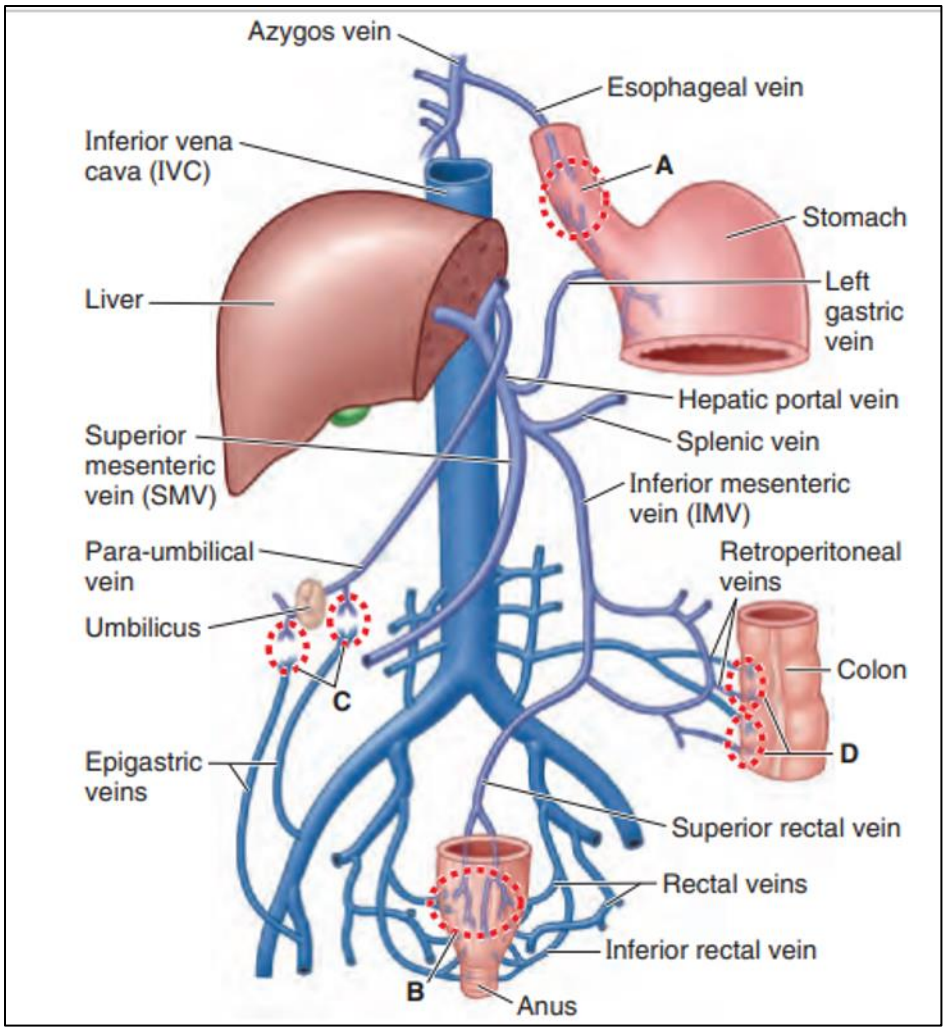

Tributaries of hepatic portal vein and portal–systemic anastomoses.

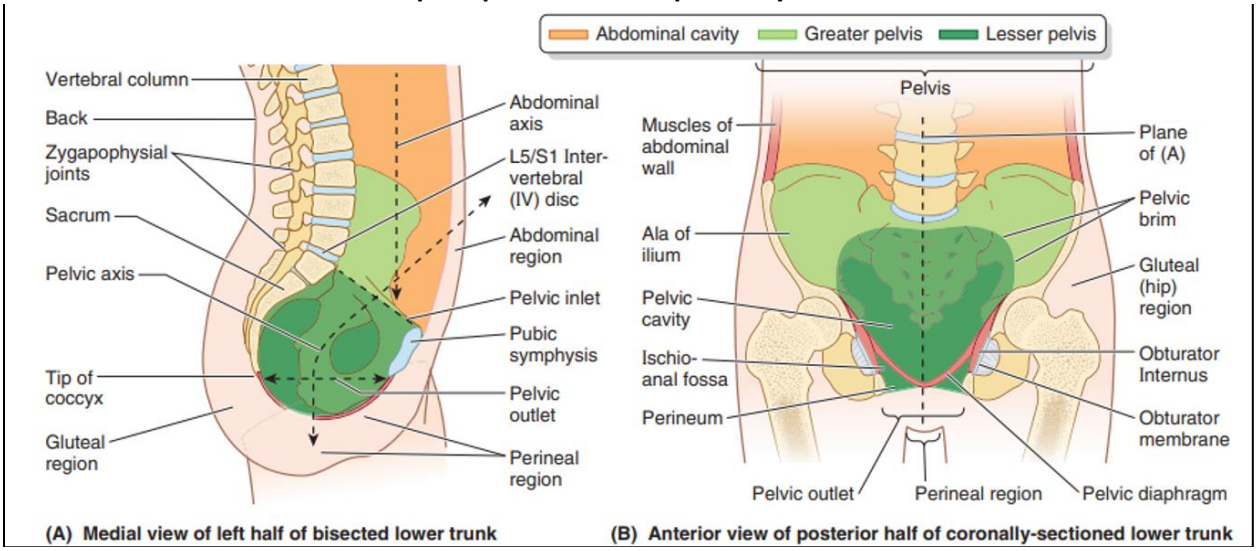

Divisions of the pelvis and perineum.

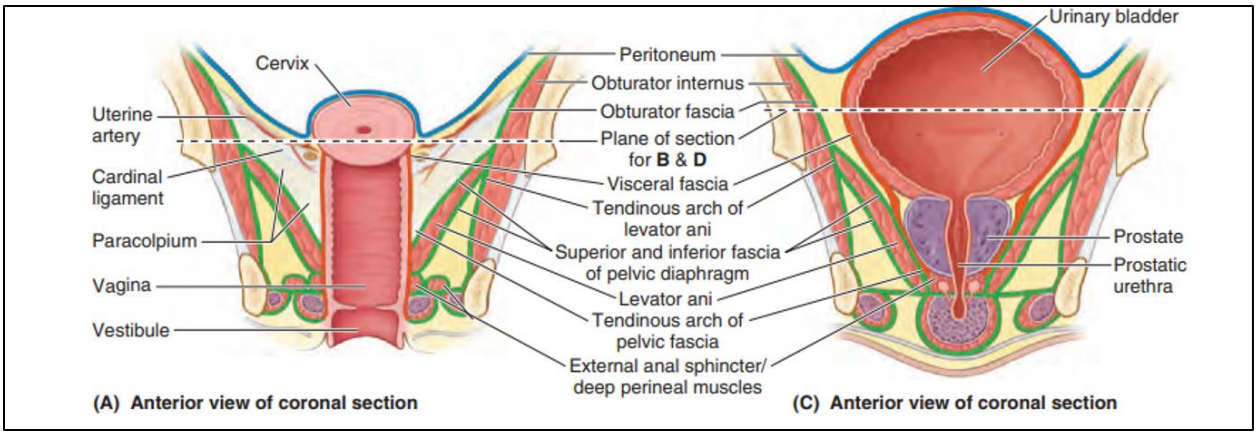

Coronal section of the male and female pelvis showing the distribution and relationships of the pelvi fascia

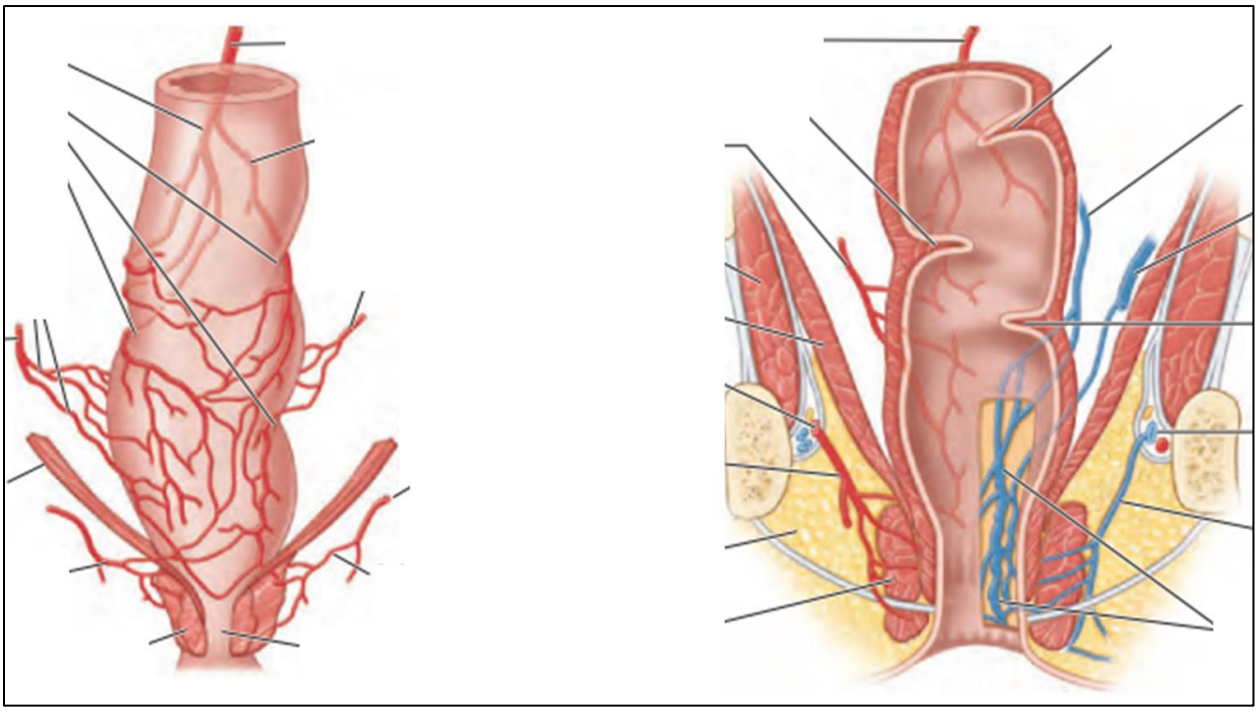

Blood supply of the rectum and anal canal.

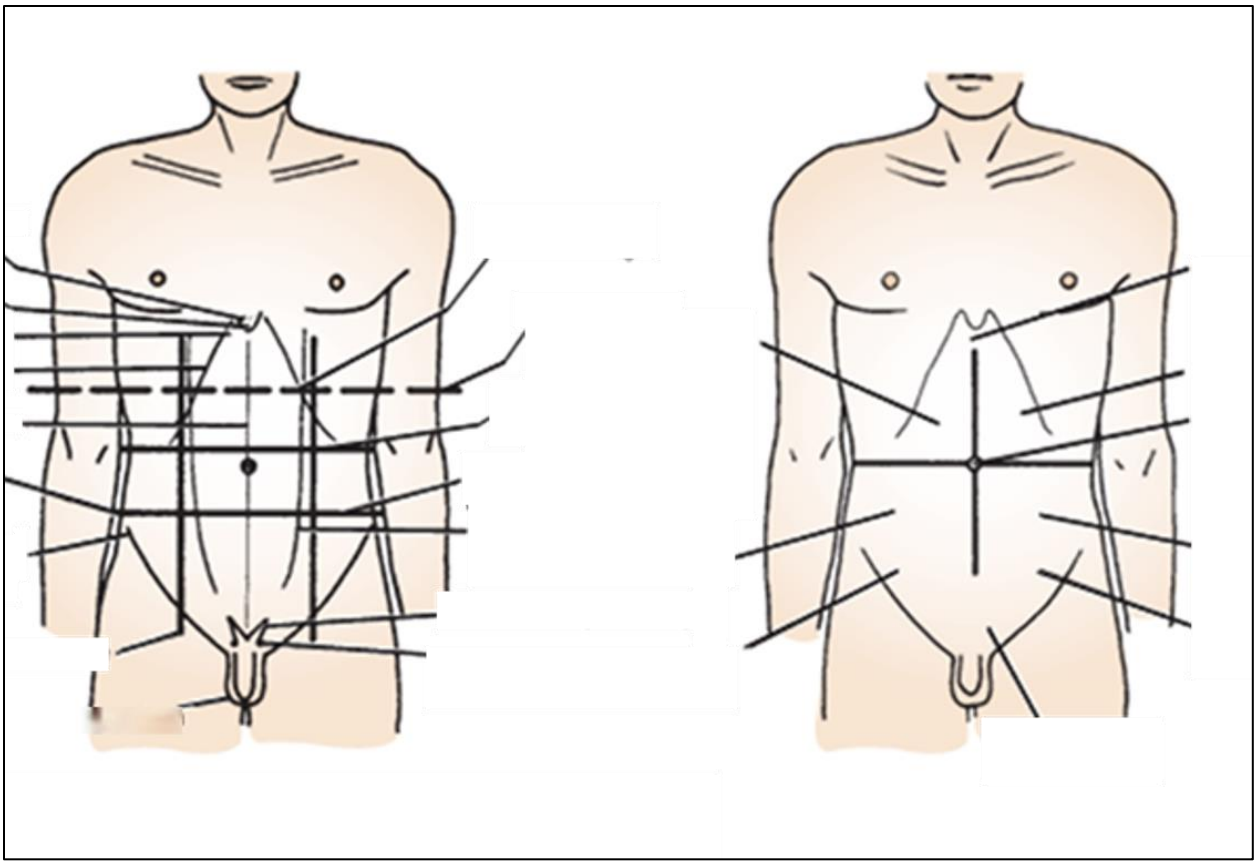

Regions and bony landmarks of the anterior abdominal wall.

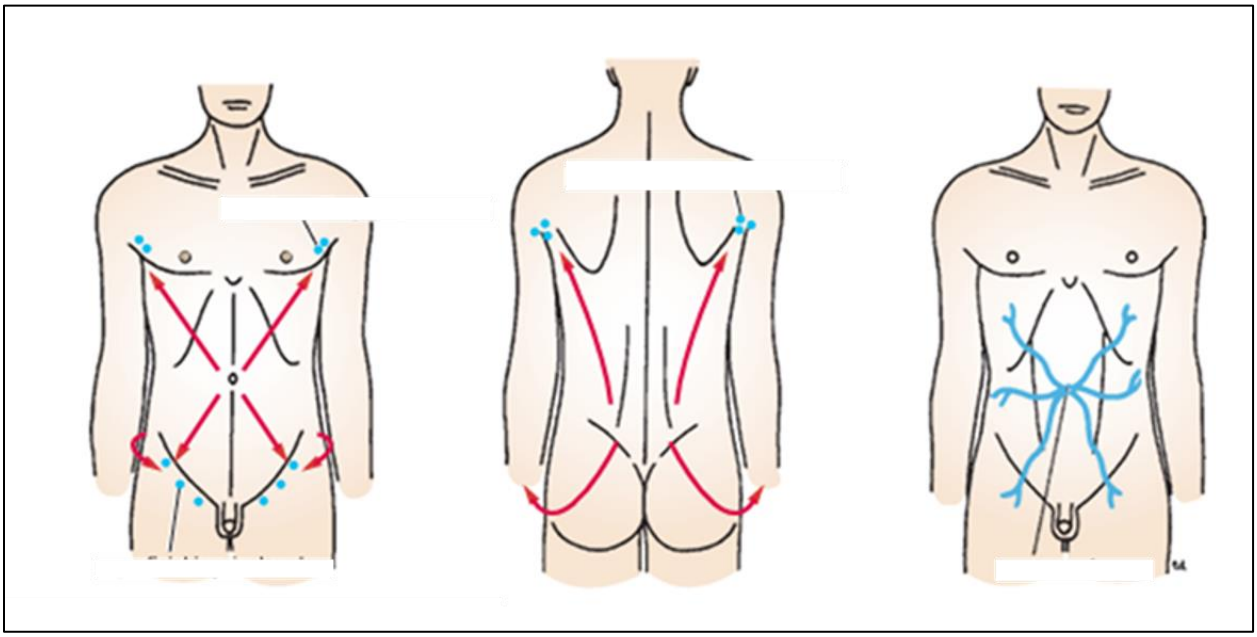

Water shed line of the abdomen.